

Oral N-Acetyl Cysteine for Meconium Ileus of Preterm Infants

Gulsum KADIOGLU SIMSEK¹, Sema ARAYICI², Mehmet BUYUKTIRYAKI¹, Nilufer OKUR¹,
Gozde KANMAZ KUTMAN¹, Serife SUNA OGUZ¹

Ankara, Turkey

ABSTRACT

OBJECTIVE: Meconium ileus of preterm infant is a kind of intestinal obstruction. There is no standard medical treatment of meconium ileus of preterm infant.**STUDY DESIGN:** During the study period, preterm infants under 1.250 g and have clinical signs of meconium obstruction were retrospectively included in the study. In the first two days, rectal saline and metoclopramide started and if not respond these infants assigned to receive oral or rectal n-acetyl cysteine and control group remained to receive a saline enema.**RESULTS:** One hundred and twenty-one infants were included in the study. Thirty-four of them received oral n-acetyl cysteine (group 1) and fifty-two had treated with rectal n-acetyl cysteine (group 2), thirty-five of them served as a control group (group 3). The mean gestational ages were 28, 28, 27 weeks and birth-weights were 942, 1.010, 965 grams for group 1 & 2 & 3 respectively. There was a difference between groups for reaching full enteral feedings (13±2, 13±3, 15±3, group 1 & 2 & 3 respectively, $p=0.001$).**CONCLUSION:** According to this study, it can be stated that orally administered n-acetyl cysteine is tolerable and as effective as rectal n-acetyl cysteine when used for MIPI.**Keywords:** Meconium ileus, Meconium plug, N-acetyl cysteine, Preterm infant*Gynecol Obstet Reprod Med 2019;25(3):169-173*

Introduction

Delayed passage of first stool by a newborn after birth might be an initial sign of clinical problems, such as meconium ileus, meconium plug syndrome, intestinal atresia, and other forms of gastrointestinal obstructions (1). Delayed passage of first stool has been observed in preterm newborns, and there was an inverse relationship between gestational age and time of first stool passage (2-5). In the last 20 years, there are

forms of intestinal obstruction-like syndromes associated with delayed meconium passage in preterm infants. Meconium ileus of preterm infant (MIPI) is a kind of functional obstruction that is not associated with atresias and cystic fibrosis but it can be defined as mechanical obstruction of ileum or colon with seared and thickened meconium. Meconium plug, meconium obstruction, premature bowel obstruction, meconium ileus, meconium blockage, and inspissated meconium are all used for defining this gastrointestinal condition. There are several types of management strategies to overcome this condition because this leads to delay in early feeding and feeding intolerance. Treatment may be medical and/or surgical. In medical approach, there are starting early enteral feedings, contrast enema, saline rectal irrigations, rectal n-acetyl cysteine (NAC) irrigations, prokinetic drugs and orally administered NAC. To the best of our knowledge, there is no clear data showing any advantages or superiorities of these treatments comparing each other. We aimed to evaluate the safety, tolerability, and effectiveness of orally administered NAC compared to rectal NAC in MIPI.

Material and Method

This study was conducted in Neonatal Intensive Care Unit, Zekai Tahir Burak Women's Health Education and Research Hospital. Infants under 30 gestational weeks (GW) and birth weight (BW) under 1250 g were subjected to this retrospective observational study. Between June 2013 and December 2014, 132 preterm infants were enrolled and 114 of them completed

¹ Department of Neonatology, NICU, Zekai Tahir Burak Education and Research Hospital, Ankara, Turkey² NICU, Çanakkale State Hospital, Çanakkale, Turkey

Address of Correspondence: Gulsum Kadioglu Simsek
Department of Neonatology, NICU, Zekai
Tahir Burak Education and Research
Hospital, 06230 Hamamonu, Altindag
Ankara, Turkey
glsmkadioglu@gmail.com

Submitted for Publication: 08.03.2018

Revised for Publication: 25.03.2018

Accepted for Publication: 08.04.2018

ORCID IDs of the authors:

GKS: 0000-0003-4831-8950, SA:0000-0002-5389-1834

MB: 0000-0001-8937-4671, NO: 0000-0002-0027-0532

GKK: 0000-0002-3177-9411, SSO: 0000-0002-2066-1186

Quick Response Code:	Access this article online
	Website: www.gorm.com.tr e-mail: info@gorm.com.tr
	DOI:10.201613/GORM.2019.930

How to cite this article: Kadioglu Simsek G. Arayici S. Buyuktiryaki M. Okur N. Kanmaz Kutman G. Suna Oguz S. Oral N. Acetyl Cysteine for Meconium Ileus of Preterm Infants. *Gynecol Obstet Reprod Med.* 2019;25(3):169-173

the study, 18 excluded due to lost of follow up and insufficient clinical data. Infants who had major congenital anomalies, low life expectancy, chronic illnesses, delayed respiratory support requirement, sepsis and finally diagnosed a surgical condition.

Small for gestational age (SGA) was defined as birth weight below the 10th percentile. Sepsis classified early onset sepsis (EOS) as the onset of symptoms before 72 h of life and late-onset sepsis (LOS) 3-30 days of life. Intraventricular hemorrhage (IVH) is graded according to the Papile grading system. Bell Staging has used in assigning severity of the disease to Necrotizing enterocolitis (NEC) cases.

Feeding protocol in our NICU

Parenteral nutrition was initiated right after delivery for all infants. Amino acids (TrophAmine 6%, Baxter, Istanbul, Turkey) were started at a dose of 2.3 g/kg/day and reached 4 g/kg/day on the third day of life, while lipid emulsion (Lipofundin MCT/LCT 20%, B. Braun Melsungen AG, Germany) was started at a dose of 1 g/kg/day on the second day of life, reaching 3-4 g/kg/day on the fourth day life. Parenteral glucose was started at 6 mg/kg/min on the first day of life and increased as tolerated to 12 mg/kg/min. All enrolled patients received 80-100 kcal/kg/day at the end of the first week. Minimal enteral nutrition with full strength human milk was initiated within the first day of life at a dose of 10-20 ml/kg/day and it was increased as tolerated due to the nutrition protocol of the nursery in the second week of life.

Full enteral feeding was defined as 150-170 ml/kg/day. The fortification was commenced when infants reached 80 ml/kg of enteral feeding.

Definition of meconium ileus of preterm infant

Symptoms: Significant abdominal distension without significant emesis or orogastric tube output but more than >50% gastric residuals at least two times a day.

Initial physical examination: A distended abdomen with visible bowel loops without peritoneal signs or abdominal wall discoloration.

Abdominal plain x-rays: distended loops of bowel of uniform diameter without air-fluid levels or pneumatosis intestinalis.

Delayed meconium passage was defined as the absence of first stool following meconium within 48 hours after first feeding with breast milk. If first stool passage was not occurred spontaneously during the first 48 h of life, defecation was stimulated by the administration of a saline enema (5-10 ml/kg saline solution 0.9%).

Study protocol

This was a retrospective observational study. During the study period, preterm infants under 1250 g and have clinical signs of meconium obstruction including abdominal distension, vomiting, gastric residuals, visible bowel segments on

X-ray, and lower gastrointestinal obstruction signs were included in the study. In the first two days after diagnosis rectal saline and metoclopramide started and if not respond these infants assigned to receive oral or rectal NAC.

Abdomen was assessed daily and documented to identify MIPI. Saline rectal irrigations (5-10 mL/kg every 6 hours) and metoclopramide (0.1 mg/kg/dose PO or IV every 6 hours 30 minutes before feedings) were used as first-line therapy in all infants who have MIPI. End of the first two days after rectal saline and metoclopramide started and if not respond, these infants received oral or rectal NAC due to clinician/consultant decision (Figure 1).

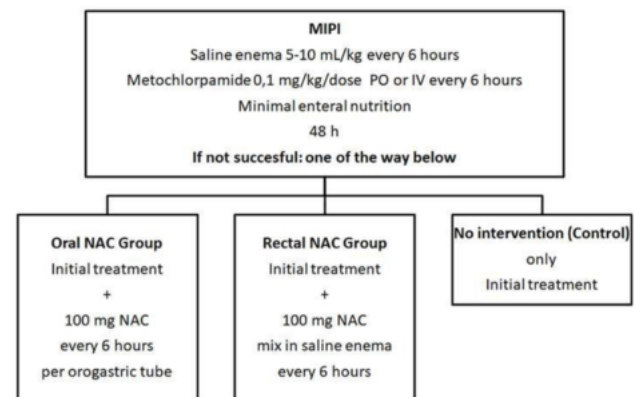


Figure 1: Study protocol

Oral NAC group: Addition of N-acetylcysteine per orogastric tube at a dose of 1 mL of 10% solution (100 mg) every 6 hours. Pure NAC solutions were prepared by mixing with a sufficient quantity of bacteriostatic 0.9% sodium chloride for injection to make a final volume of 10%, 100-mg/mL. Samples were prepared daily, placed plastic injector, and stored at 20-25 °C. Samples were assayed for pH and osmolarity immediately after preparation and at 24 hours to confirm stability and eligible for oral using.

Rectal NAC group: Administration of an enema 1 mL 10% N-acetylcysteine, 100 mg - added to 9 mL saline solution 0.9% 5-10 mL/kg every 6 hours via a disposable gastric tube coated with petrolatum (Vaseline®) for protective insertion into the rectum. Same NAC solutions also used for oral NAC group.

Control Group: No additional treatment were used after first-line therapy (Saline rectal irrigations 5-10 mL/kg every 6 hours and metoclopramide 0.1 mg/kg/dose PO or IV every 6 hours 30 minutes before feedings).

Enteral feedings were not ceased immediately after diagnosed MIPI, continued in the way that minimal enteral nutrition volumes as far as possible in all groups.

If MIPI was not resolved during the first 10 day of starting our protocol or worsened symptoms and signs anytime, we requested a pediatric surgery consultation to assign therapeutic contrast enema or enterotomy.

Each of the neonates with MIPI was also tested for hipotroidi with TSH/free T4 and cystic fibrosis using immunoreactive trypsinogen or genetic analysis.

Approval for the study was obtained from the local Ethics Committee which was placed in Zekai Tahir Burak Maternity Teaching Hospital and informed consent forms were obtained from all parents.

Statistical Analysis

SPSS version 20 (SPSS, Chicago, IL) was used for analysis. Data were expressed as mean \pm SD. Differences in the means of variables were tested using both parametric and non-parametric tests depending on the distribution of the variables. A probability value (p -value) of less than 0.05 was considered as statistically significant. T-test used for comparing indexes between groups and chi-square for categorical variables. One way ANOVA used to compare all three groups.

Results

Between June 2013 and December 2014, 132 preterm infants were collected retrospectively as having MIPI and were enrolled to study. 121 of them completed the study, 11 excluded due to loss of follow up and insufficient clinical data. Oral NAC group has 34, Rectal NAC group has 52 and Control group has 35 patients.

Mean gestational age was 28.5 (\pm 2.4) weeks oral NAC group, 28 (\pm 2) weeks rectal NAC group and 27.4 (\pm 2) weeks control group. Mean birth weight was 942 (\pm 191) g oral NAC group, 1010 (\pm 196) g rectal NAC group and 965 (\pm 145) g control group.

Male gender was 50% (n=17) in oral NAC group, 50% (n=26) in rectal NAC group, %45 (n=16) in control group. SGA was 47% (n=16) in oral NAC group, 32% (n=17) in rectal NAC group, %45 (n=16) in control group (Table I).

Perinatal and maternal history

Major complications of pregnancies had including, premature labor and premature rupture of membranes, oligohydramnios, placental abruption, preeclampsia, gestational diabetes mellitus, and hypothyroidism. Preeclampsia was reported for 17 (50%) oral NAC group, 18 (34%) rectal NAC group, 13 (27%) control group, $p=0.3$. The percentages of infants who received a course of steroids before delivery were also similar between study groups, 70% (n=24) oral NAC group, 69% (n=36) rectal NAC group, and 65% (n=23) control group, $p=0.9$. There was no mother using opioids or magnesium sulfate therapy.

Clinic and diagnostic data

Initial clinical signs of MIPI was similar for all patients,

Table I: Clinical characteristics of study population and comparison of three groups

	Group 1 oral NAC n=34	Group 2 rectal NAC n=52	Control group n=35	p value
Gestational age, week, \pm SD	28.5 \pm 2.4	28 \pm 2	27.4 \pm 2	0.56
Birthweight, g, \pm SD	942 \pm 191	1010 \pm 196	965 \pm 145	0.211
Male, n (%)	17 (50)	26 (50)	16 (45)	0.913
Resuscitation, n (%)	12 (35)	16 (47)	6 (17)	0.2
Small for gestational age, n (%)	16 (47)	17 (32)	16 (45)	0.314
Antenatal steroids, n (%)	24 (70)	36 (69)	23(65)	0.9
Maternal hypertension, n (%)	17 (50)	18 (34)	13 (27)	0.3
Maternal diabetes mellitus, n (%)	1 (3)	4 (7.7)	0 (0)	0.19
Maternal opioid, n (%)	0	0	0	
Maternal MgSO ₄ , n (%)	0	0	0	
Oligohydramnios, n (%)	6 (17)	7 (13)	1 (3)	0.13
Umbilical catheterization, n (%)	34 (100)	48 (92)	35 (100)	0.06
Any type of mechanical ventilation, n (%)	32 (94)	49 (94)	35 (100)	0.34
RDS, n (%)	26 (76)	42 (80)	35 (100)	0.01
Hypoglycemia, n (%)	4 (11)	16 (30)	10 (28)	0.2
PDA, n (%)	9 (26)	19 (36)	18 (51)	0.09
Early onset Sepsis, n (%)	9 (26)	16 (30)	7 (20)	0.53
Late onset Sepsis, n (%)	17 (50)	26 (50)	22 (62)	0.43
Intracranial hemorrhage (\geq Grade 3), n (%)	9 (26)	13 (26)	10 (28)	0.32
NEC, n (%)	0 (0)	1 (2)	4 (11)	0.033
Mortality, n (%)	3 (9)	2 (4)	2 (5)	0.15
Hospitalization, day, \pm SD	65 \pm 15	61 \pm 21	68 \pm 22	0.33
Day of first signs, day, \pm SD	5 \pm 2	5.8 \pm 2	7 \pm 1	0.001
Reach of full enteral feeding, day, \pm SD	13.4 \pm 2.3	13.4 \pm 3.6	15.9 \pm 3.2	0.001
First stool, day, \pm SD	1.6 \pm 0.6	1.7 \pm 0.7	2 \pm 0.5	0.082
Day of resolution of signs, day, \pm SD	12 \pm 3	10 \pm 3	15 \pm 3	0.001

NAC: N-acetylcysteine, RDS: Respiratory distress syndrome, PDA: Patent ductus arteriosus, NEC: Necrotizing enterocolitis,

such as significant abdominal distension and gastric residuals. All patients had been fed and most of them had passed small amount of meconium smears, before diagnosis. In physical examination at the diagnosis of MIPI, we found distended abdomen and visible bowel generally and following abdominal plain x-rays showed distended loops of bowel. All patients hemodynamically stable at initial presentation and metabolic acidosis was absent. All patients were tested for and hypothyroidism and cystic fibrosis, all results were negative.

The average postnatal day at diagnosis of meconium obstruction was 5 ± 2 days oral NAC group, 5.8 ± 2 days rectal NAC group and 7 ± 1 days control group, $p=0.001$.

Clinical morbidities typically associated with prematurity were common and included respiratory distress syndrome 26 (76%), 49 (94%), 35 (100%), $p=0.01$, patent ductus arteriosus 9 (26%), 19 (36%), 18 (51%), $p=0.09$, intraventricular hemorrhage 9 (26%), 13 (26%), 10 (28%), $p=0.32$ and hypoglycemia 4 (11%), 16 (30%), 10 (28%), $p=0.2$, for oral NAC, rectal NAC and control group respectively. All patients with PDA received ibuprofen or paracetamol, and none of them required surgical closure. There were no significant differences among the 3 groups in umbilical catheterization ($p=0.06$), any type of mechanical ventilation ($p=0.34$), early-onset sepsis ($p=0.53$) and late-onset sepsis ($p=0.43$). All patients were mechanically ventilated (intubated or nasal IMV/CPAP) after birth and were mechanically ventilated at the time of diagnosis. NEC was diagnosed more commonly among study groups (none oral NAC group, 1 (%2) rectal NAC group) than the control group (4 (%11), $p=0.033$).

Treatment and outcome

The mean time to first stool passage in the oral NAC group 1.6 ± 0.6 days, in rectal NAC group 1.7 ± 0.7 days and control group 2 ± 0.5 days, $p=0.082$. None of the infants received glycerin suppositories or rectal stimulation before first stool. Stool passage was typically infrequent or in small amounts.

Resolution of obstruction occurred postnatal $12.3 \pm$ days oral NAC group, 10 ± 3 days rectal NAC group, 15 ± 3 days control group, this association was statistically significant by one way ANOVA test ($p=0.001$). The day of resolution of obstruction also compared infants managed oral NAC with control group ($p=0.02$) and rectal NAC with control group ($p=0.005$).

Enteral feedings were started the first day of life and volumes were increased gradually according to tolerance. After the diagnose of MIPI, enteral feedings were not discontinued just were decreased unto minimal enteral nutrition volume. Full enteral feeding achieved 13.4 ± 2.3 days oral NAC group, 13.4 ± 3.6 days rectal NAC group and 15.9 ± 3.2 days control group, $p=0.001$ by one way ANOVA. Both study groups compared with the control group by *t*-test, *p*-value was 0.002 in oral NAC with control group and 0.001 in rectal NAC with control group (Table II).

Table II: *P*-values for comparison of oral *N*-acetylcysteine and rectal *N*-acetylcysteine to controls

	Oral NAC/ controls <i>p</i> -value	Rectal NAC/ controls <i>p</i> -value
Day of first stool passage	0.017	0.176
Day of first signs	0.01	0.006
Day of resolution of signs	0.02	0.005
Reach of full enteral feeding	0.002	0.001

NAC: *N*-acetylcysteine

None of infants were given a contrast enema. Mean hospital stay was 65 ± 15 days in oral NAC group, 61 ± 21 days in rectal NAC group and 68 ± 22 days in the control group ($p=0.33$). Mortality rate did not differ between groups, 9% in oral NAC group, 4% in rectal NAC group and 5% in the control group, $p=0.15$.

(Posthoc power analysis revealed that with an average of reaching full enteral feedings by 15th day of life to reduce 13th day of life, with a standard deviation of 3, α error level 5%, as a result of this calculation was 92%.)

Discussion

Meconium obstruction in low birth weight infants was firstly reported in 1979 as a case report of three patients by Siegel et al (6). Four years after that Vinograd et al. described it as "meconium disease" in 1983 in a report of seven patients (7). Krasna et al. reported meconium obstruction in 20 low-birth weight infants in 1996 (8). All these reports described a mild form of the disease and all these reported infants did not require surgery. However, very soon after the last report in 1996, Greenholz et al. (9) reported 12 infants with inspissated meconium syndrome requiring surgery, eight cases of which were caused by intestinal perforation.

After the survival of very preterm infants incidence of this clinical situation had increased. Finally, MIPI (10) used to describe this gastrointestinal condition and to the best of our knowledge this study is the first study that compares oral and rectal NAC in MIPI. We compared these two methods to control (rectal saline) and both seem safe and effective and may be used as alternative methods to solve meconium plug in preterm neonates. Our findings support the hypothesis that resolution of meconium plug by *n*-acetyl cystein helped to reach full enteral feedings earlier.

The main problem for feeding intolerance and delayed passage of meconium in very low birth weight infants is immaturity of the gastrointestinal system (11). The timing of the first stool plays a critical role in the motor function of bowel (12). There are also some prenatal and postnatal risk factors such as maternal hypertension, preeclampsia, intrauterine growth restriction, small for gestational age infants (13), hemodynamic disturbances have been identified for MIPI (14).

An additional important risk for MIPI is surgery (15). If

not treated or there is a delay for starting enteral feedings there will be a vicious circle. Meconium will be thicker, no feed no motility, prolonged parenteral nutrition, and more cholestasis. After this complications, surgery would be inevitable. So MIPI is not only a medical problem is also a surgical problem for very preterm infants (16).

As a result of definition problems and lack of standard approaches to MIPI, there are not enough clinical trails addresses to reach early full enteral feedings in very low-birth weight infants with MIPI (17). There are only six trials in a recent meta-analysis and all have the small sample size and some of them heterogenic (17). As a result of these limitations this recent systematic review suggested that the use of a glycerine suppository, small-volume enema with glycerine or normal saline, or the administration of an oral osmotic agent, such as gastrografin, to evacuate the meconium did not reduce the time to reach full enteral feeds in very low birth weight neonates (17). However, we observed a difference by rectal and oral NAC administration especially on reaching earlier full enteral feeding when compared to saline enema in infants with MIPI.

Why we used oral NAC? Rectal NAC can reach only distal region of the plug and may only decompose meconium by one side. Anatomically there may be more plugs in the proximal regions. Orally administered drugs may trigger intestinal motility and can reach both proximal and distal plugs.

As a conclusion, we compared for the first time, rectal and oral NAC in infants with MIPI and did not observe any difference between these groups according to reach full enteral feeding, hospitalization and other parameters but seems better than saline enema. Our findings supported the hypothesis that rectal or oral NAC may reduce the delay of reaching full enteral feedings in infants with MIPI. There may be more trials with different approaches to better understand and ameliorate MIPI in very low birth weight infants.

Acknowledgement: None. Funding: There is nothing to disclose. Conflict of interest: Nothing to declare. Research involving human participants and/or animals: Ethical approval obtained from local ethical committee Date and number: 27.06.2013-41. Informed consent: Informed consent was obtained for using data.

This study was conducted in accordance with the Declaration of Helsinki.

Author Contributions: GKS:., MB.:, Concept, Data processing, analysis, and interpretation, Writer. SA:., NO: Data collection, Processing, Analysis, and interpretation. GKK: Supervision, Concept, Design, Data collection and processing, Statistical analysis and Data interpretation. SSO: Supervision, Concept, design, Analysis and Interpretation

References

1. Dimmitt RA, Moss RL. Meconium diseases in infants with very low birth weight. *Semin Pediatr Surg.* 2000; 9(2):79-83.
2. Kumar SL, Dhanireddy R. Time of first stool in premature infants: Effect of gestational age and illness severity. *J Pediatr.* 1995;127(6):971-4.
3. Wang PA, Huang FY. Time of the first defaecation and urination in very low birth weight infants. *Eur J Pediatr.* 1994;153(4):279-83.
4. Jhaveri MK, Kumar SP. Passage of the first stool in very low birth weight infants. *Pediatrics.* 1987;79(6):1005-7.
5. Weaver LT, Lucas A. Development of bowel habit in preterm infants. *Arch Dis Child.* 1993; 68 (3 Spec No): 317-20.
6. Siegel MJ, Shackelford GD, McAlister WH. Neonatal meconium blockage in the ileum and proximal colon. *Radiology.* 1979;132(1):79-82.
7. Vinograd I, Mogle P, Peleg O, Alpan G, Lernau OZ. Meconium disease in premature infants with very low birth weight. *J Pediatr.* 1983;103(6):963-6.
8. Krasna IH, Rosenfeld D, Salerno P. Is it necrotizing enterocolitis, microcolon of prematurity, or delayed meconium plug? A dilemma in the tiny premature infant. *J Pediatr Surg.* 1996;31(6):855-8.
9. Greenholz SK, Perez C, Wesley JR, Marr CC. Meconium obstruction in the markedly premature infant. *J Pediatr Surg.* 1996;31(1):117-20.
10. Garza-Cox S, Keeney SE, Angel CA, Thompson LL, Swischuk LE. Meconium obstruction in the very low birth weight premature infant. *Pediatrics.* 2004;114(1):285-90.
11. Newell SJ. Enteral feeding of the micropremie. *Clin Perinatol.* 2000;27(1):221-34.
12. Meetze WH, Palazzolo VL, Bowling D, Behnke M, Burchfield DJ, Neu J. Meconium passage in very low birth weight infants *JPEN J Parenter Enteral Nutr.* 1993; 17(6):537-40.
13. Raith W, Resch B, Pichler G, Zotter H, Urlesberger B, Mueller W. Delayed meconium passage in small vs. appropriate for gestational age preterm infants: management and short-term outcome. *Iran J Pediatr.* 2013;23(1):8-12.
14. Tsukamoto H, Fukuoka H, Koyasu M, Nagai Y, Takimoto H. Risk factors for small for gestational age. *Pediatr Int.* 2007;49(6):985-90.
15. Karimi A, Gorter RR, Sleeboom C, Kneepkens CM, Heij HA. Issues in the management of simple and complex meconium ileus. *Pediatr Surg Int.* 2011;27(9):963-8.
16. Burge D, Drewett M. Meconium plug obstruction. *Pediatr Surg Int.* 2004;20(2):108-10.
17. Deshmukh M, Balasubramanian H, Patole S. Meconium evacuation for facilitating feed tolerance in preterm neonates: A systematic review and meta-analysis. *Neonatology.* 2016;110(1):55-65.