

Bilateral Borderline Serous Ovarian Tumor Following Three Cycles of Clomiphene Treatment in 19 Years Old Subfertile Woman with Polycystic Ovaries: A Case Report

Orhan GELİŞEN, Müberra KOÇAK, Faruk KÖSE, Nurettin BORAN, Berfu DEMİR, Ahmet ÖZFUTTU
Ankara-Turkey

Clomiphene Citrate (CC) is one of the most comprehensively registered agent for ovulation induction in women with polycystic ovarian syndrome (PCOS). CC is regarded as safe and cost effective agent with very few complications. During the last 20 years, the potential association between the use of ovulation induction agents and the risk of ovarian neoplasm has become a topic of considerable scientific and public health interest.

We report a woman who developed bilateral serous borderline ovarian tumor following three cycles of CC from normal appearing ovaries. The condition was diagnosed using baseline ultrasound of the aftercoming CC cycle and immediate diagnostic laparoscopy followed by a converting laparotomy for an accurate staging was performed.

We also review published case reports of borderline ovarian tumors following ovulation induction to update the medical literature about this rare yet serious condition may be encountered by physicians providing infertility treatment. A borderline ovarian neoplasm in polycystic ovaries should be considered if a patient develops unforeseen ovarian mass (es) following ovulation induction.
(*Gynecol Obstet Reprod Med* 2006; 12:147-149)

Key Words: Clomiphene citrate, Infertility, Borderline ovarian tumors

A 19 years old nulliparous woman with a three years infertility was referred to our infertility unit for ovulation induction is presented. The woman had a history of oligomenorrhea since her menarch, with normal hormonal work-up. Her partner had normospermia and her waist to hip ratio (WHR) and Body Mass Index (BMI) were normal with 0.72 and 23.5kg/m², respectively. On baseline ultrasound, the patient's ovaries contained multiple antral follicles and surrounding hyperplastic ovarian stroma. The case had no inherited risk factors for ovarian cancer or any metabolic disease. She was diagnosed as PCOS and ovulation induction was initiated by standard regime of clomiphene therapy started with a single 50-mg daily for a 5-day interval in three subsequent cycles. The cycles were monitored only of ultrasound folliculometric measurements and no serum estradiol measurements. During the three CC treatment cycles, transvaginal ultrasonography had shown no evidence of intraovarian pathology. In each treatment midcycle, there were one to three follicles between 18-23 mm in diameter, she received 10.000 IU of hCG at that time.

Baseline transvaginal ultrasonography for the fourth treatment cycle implied bilateral solid adnexal masses with

Kadın Hastalıkları ve Doğum, İnfertilite Kliniği, TCSB Ankara Etlik Doğumevi, Kadın Hastalıkları Eğitim Araştırma Hastanesi, Ankara

Address of Correspondence Müberra Koçak

TCSB Ankara Etlik Doğumevi

KHEA Hastanesi, Ankara

Submitted for Publication: 13.05.2006

Accepted for Publication: 12.06.2006

normal tumor markers and Doppler values (PI:1, RI:0.6, Cal25:29 IU/ml) and minimal ascites in the case who presented to our infertility unit with mild abdominal pain. The case underwent an immediate diagnostic laparoscopy, both ovaries appeared markedly enlarged, measuring 7-8 cm in thickness throughout with areas of papillary projections. (Figure 1) Frozen section in laparoscopic tissue biopsies revealed bilateral borderline serous ovarian tumor and then, a converting laparotomy was performed for an accurate staging procedure. Bilateral ovarian wedge resection were done to excise tumoral tissue from normal appearing ovarian tissue and adhesion barriers applied (Figure 2). According to full staging, the case was diagnosed as Stage IB serous borderline ovarian tumor. No complication occurred after the operation and spontaneous menstrual cycles resumed for the first time. No further treatment, such as ovulation induction was proposed for one year and the patient now comes for regular follow-up to our outpatient clinic.

Discussion

Development of ovarian neoplasm associated with ovarian stimulation is an uncommon yet potentially fatal condition of assisted reproductive technology. Knowledge about its pathogenesis and prevention is limited. Several cohort studies and case-control studies on ovarian neoplasm have analyzed the relationship.^{1,2,3,4} Ness RB et al. from their 8 case-control studies found that ovulation induction among nulliparous women was associated with a small increase in the incidence of borderline serous ovarian tumours (OR:2.43, CI:1.01-5.88), but not with any invasive cancers (OR:1.60, CI:0.90-2.87).⁵

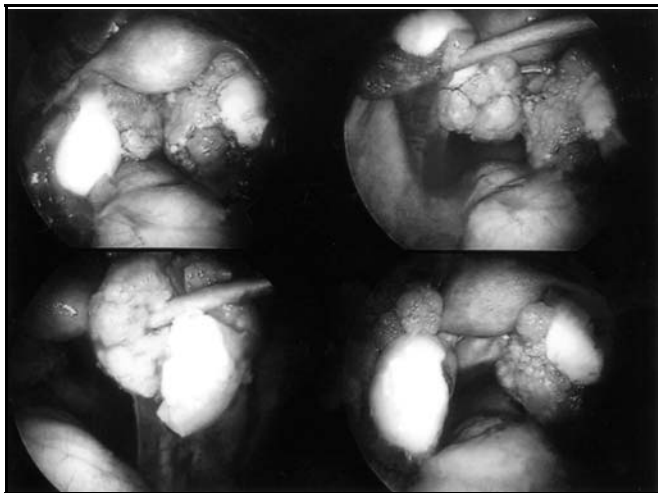


Figure 1. Bilateral borderline tumour measuring 7-8 cm in diameter arising from the normal appearing ovaries, previously.

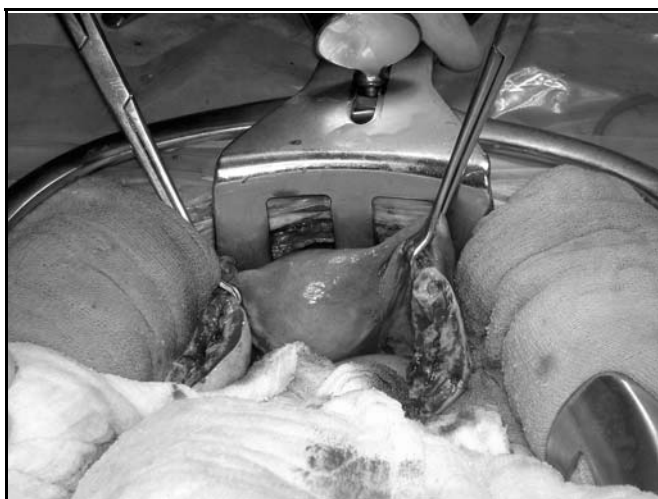

Figure 2. Bilateral ovarian wedge resection along the affected ovarian stroma was made at the staging laparotomy.

As the present case report, several case reports and the results of recent case-control studies have raised questions about potential neoplastic effects of ovulation induction agents used as anovulatory infertility treatment. Rossing MA et al detected 11 ovarian tumours in a cohort of 3837 infertile women and found that relative risk for ovarian cancer in such group of women was 11.1 with 95% confidence interval versus 1.5 with 82.3% confidence interval in the control cohort who did not received ovulation induction therapies. They also concluded that prolonged use of ovulation induction agents might increase the risk of ovarian neoplasm.¹

As far as we noticed in the literature, the present case is the youngest report of bilateral borderline ovarian tumor following a short term-low dose of CC treatment in a 19 year old infertile woman with PCOS. Salle B et al reported two cases of ovarian neoplasm in women who had undergone multiple ovulation induction cycles and their conclusion is consistent with the "incessant ovulation" or "high level of gonadotrophins" hypothesis.⁶ Rossing MA et al. conducted

a population-based, case-control study with 378 cases and, 1637 controls. They concluded that ovarian neoplasm risk at late reproductive life was increased among women with a history of infertility.⁷ Our case report support the hypothesis that a subset of infertile young women may be increased risk of ovarian neoplasm and few of such reports have been described in the literature. Whether use of CC triggers this increase in risk remain unclear. Reports are also scarce for complications of ovulation induction with the use of CC and none have associated with short term treatment cycles. This finding prompted us to investigate the possibility that CC may induce borderline ovarian tumours, either by directly on subtle neoplastic tissue at the ovarian stroma or yet undescribed mechanism.

Recently, the question of ovulation induction in cases of persistent infertility after fertility sparing surgery in borderline ovarian tumours has opened to debate by Morice P.⁸ Most of borderline tumours are diagnosed at reproductive age, its treatment preserving fertility potential has been performed widespreadly in the last decade as was the case with our patient. It seems that the use of ovulation induction by gonadotrophins could have been proposed in the present case whenever anovulatory cycles resumed.

Ayhan A et al reached to the point under the light of previous data that the risk of borderline ovarian tumors might increase by the use of ovulation inducing agents, but not breast and invasive ovarian cancers. They also underlined the fact that cancers are overdiagnosed in infertile women cohort because of meticulous clinical surveillance, that might contributory factor to promptness of ovarian neoplasm diagnosis in the present case.⁹

Although at present case report, there is insufficient evidence to conclude a causal relationships between fertility drugs and borderline ovarian tumors, the case was presented to pay attention to the fact that routine baseline physical examination or ultrasonography is necessary in each clomiphene cycle. We believe that women with polycystic ovaries who have been treated with clomiphene should be monitored more rigorously.

References

1. Rossing MA, Daling JR, Weiss NS, Moore DE, Self SG. Ovarian tumors in a cohort of infertile women. *N Engl J Med* 1994; 331:771-6.
2. Harris R, Whittemore AS, Intyre J. Collaborative Ovarian Cancer Group: Characteristics relating to ovarian cancer risk: collaborative analysis of 12 US case-control studies. *Am J Epidemiol* 1992; 136:1204-11.
3. Venn A, Watson L, Lumley J, Giles G, King C, Healy D. Breast and ovarian cancer incidence after infertility and in vitro fertilization. *Lancet* 1995; 346:995-1000.

4. Parazzini F, Negri E, La Vecchia C, Moroni S, Franceschi S, Crosignani PG. Treatment for infertility and risk of invasive epithelial ovarian cancer. *Hum Reprod* 1997; 12:2159-61.
5. Ness RB, Cramer DW, Goodman MJ. Infertility, fertility drugs, and ovarian cancer: a pooled analysis of case-control studies. *Am J Epidemiol* 2002; 155:217-25.
6. Salle B, de Saint Hilaire P, Devouassoux M, Gaucherand P, Rudigoz C. Another two cases of ovarian tumours in women who had undergone multiple ovulation induction cycles. *Hum Reprod* 1997; 12:1732-5.
7. Rossing MA, Tang MT, Flagg EW, Weiss LK, Wicklund KG. A case-control study of ovarian cancer in relation to infertility and the use of ovulation-inducing drugs. *Am J Epidemiol* 2004; 160:1070-8.
8. Morice P. Borderline tumours of the ovary and fertility. *Eur J Cancer* 2006; 42:149-58.
9. Ayhan A, Salman MC, Çelik H, Dursun P, Özyüncü O, Gültekin M. Association between fertility drugs and gynecologic cancers, breast cancer, and childhood cancers. *Acta Obstet Scand* 2004; 83:1104-11.