

# Bilateral Fibroepithelial Polyps of The Lower Female Genital Tract With Atypical Stromal Cells (Pseudosarcoma Botryoides): A Case Reports

Fazlı DEMİRTÜRK<sup>1</sup>, Engin ŞENER<sup>2</sup>, Ahmet Cantuğ ÇALIŞKAN<sup>1</sup>, Hakan AYTAN<sup>1</sup>  
Tokat-Turkey

A case of female genital tract fibroepithelial polyps containing atypical stromal cells arising from the vulva is described. Fibroepithelial stromal polyps of the vulvovaginal lesion are benign lesions that, when bland or hypocellular, are readily recognized. The tumor was multipl and the highest one measured 4 centimeter in diameter. Cytologic atypia has been a previously recognized feature in these lesions; however fibroepithelial polyps with stromal atypia are an uncommon tumor of the vulva, are rarely bilateral and combination of these features has only rarely been documented. These tumors must be differentiated from sarcoma botryoides, which resemble both grossly and microscopically. (*Gynecol Obstet Reprod Med* 2006; 12:000-000)

**Key Words:** Fibroepithelial polyps, Atypical stromal cells, Female genital tract

Fibroepithelial stromal polyps are benign lesions that occur in a wide variety of sites including the lower female genital tract. Polypoid or grape-like masses of the vagina or cervix are always worrisome because they raise the suspicion of sarcoma botryoides. More recently, larger series showed that reported lesions in the vulva remain an atypical site for these diseases.<sup>1,2</sup> Although they are found at any age, about one third have been reported in pregnancy. They have a gross appearance of soft, translucent pedunculated mucosal lesions. These lesions could contain atypical stromal cells and the presence of such cells should not be mistaken for malignancy.<sup>3,4</sup> Both are rare and it is important to distinguish between them.

We describe a vulvar example of the condition together with atypical stromal cells. The appearance of an identical tumor on the contralateral labia compounded the difficulty in both clinical and pathological diagnosis.

## Case Report

A 18 year-old unmarried girl, first presented in 1994 with polypoid swelling of the right and left labium, which had been presented for 5 years. They were excised and no further treatment instituted. The pathological material submitted for assesment. She returned in 2005 with large polypoid lumps on both sides of clitoris and lower portion of labium majus. The clinical examination revealed to be circumscribed tumor mass of the vulva.

<sup>1</sup>Gaziosmanpaşa University Medical Faculty, Obstetrics and Gynecology Department, <sup>2</sup>Gaziosmanpaşa University Medicine Faculty, Dermatology Department, Tokat-Turkey

Address of Correspondence Ahmet Cantuğ Çalışkan

Gaziosmanpaşa University Medicine

Faculty Obstetrics and Gynecology

Department 60100 Tokat-Turkey

Submitted for Publication: 11.06.2005

Accepted for Publication: 11.06.2005

62

At operation, the polypoid tumor was attached to the left and right labium majus by a broad base. The lower genital tract was otherwise normal and the inguinal nodes were not enlarged. None of the lesions showed locally aggressive behavior. The tumors were removed by local excision and submitted for pathological assessment.

## Pathologic Findings

**Macroscopic features:** The lesions ranged in size from 1 to 4 cm in maximum dimension. The fresh specimen was described as polypoid or pedunculated in appearance which had either smooth or fissured surfaces. The cut surface was oedematous, uniform and soft. They were described as multipl cysts that were gelatinous in appearance (Figure 1).

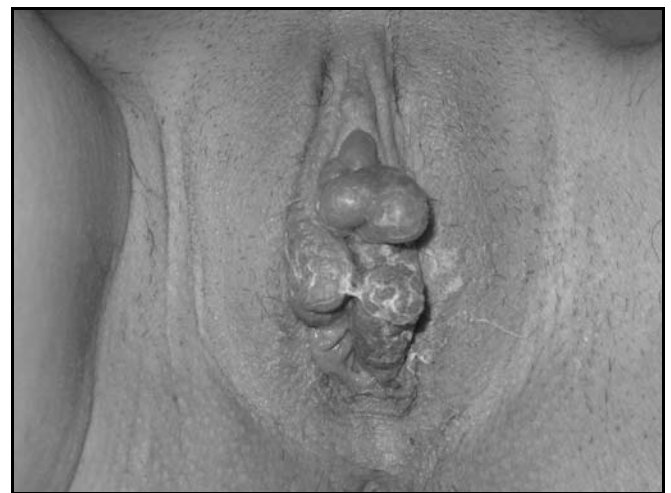

Figure 1. Fibroepithelial sessile vulvar polyps with fissured surfaces.

**Microscopic features:** The histologic features revealed loose, acellular myxoid stroma, with irregular dilated blood vessels, covered by normal squamous epithelium. On high power we observed pleomorphic fibroblast-like cells, with hyperchromatic nuclei and elongated cytoplasmic processes and sparse multinucleated giant cells (Figure 2). The micros-

copic features of the right labial lesions were identical to those of the original left labial tumor.

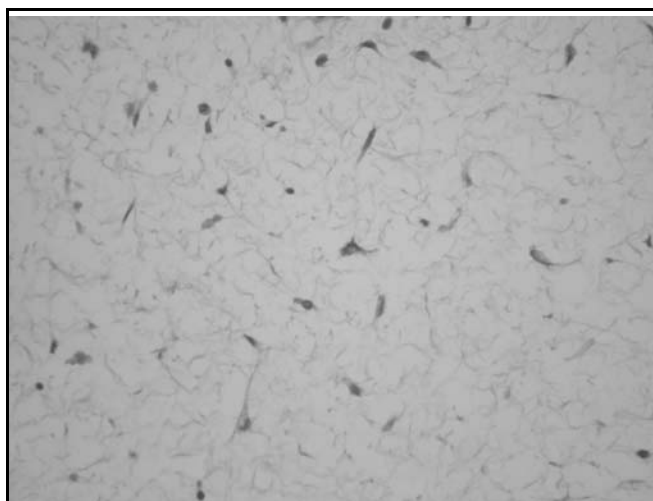


Figure 2. High power of stroma with hyperchromatic fibroblast-like cells and multinucleated giant cell. (Hematoxylin and eosin x40).

## Discussion

Pseudosarcoma botryoides of the female genital tract are benign lesions that occur generally in young to middle age women in their reproductive years.<sup>5,6,7</sup> The term is not reserved for embryonal rhabdomyosarcoma, a highly malignant tumour with poor prognosis. The term “pseudosarcoma botryoides” was applied by Elliott et al.<sup>8</sup> to emphasize its gross and microscopic resemblance to the malignant tumor and the fact that it has been confused with latter. They occur most commonly in the vagina—the site of their original description—but they can also occur in the vulva<sup>2</sup> and less commonly the cervix.<sup>9</sup> Fibroepithelial stromal polyps can occasionally recur, sometimes more than once.<sup>3</sup>

The pathogenesis of fibroepithelial polyps is poorly understood. These tumors are composed of an intimate admixture of myxoid stroma and vessels reminiscent of the submucosa of the normal uterine cervix, vagina and vulva.<sup>10</sup> The occurrence of morphologically similar cells in normal tissue and reactive processes at other anatomic locations such as breast, bladder, nasal polyps and polyps and ulcers of the gastrointestinal tract add additional support to the likely reactive nature of pseudosarcoma botryoides of the lower female genital tract. The stromal cells of fibroepithelial polyps can express estrogen and progesterone receptors, which suggests that hormonal influences may potentially play a role in the pathogenesis of these lesions. Approximately one-third of the cases of fibroepithelial polyps occur in pregnant women and another third in those who have taken sex hormone preparations. It may be that such a hormonal milieu predisposes to their formation.

In summary, pseudosarcoma botryoides of the lower female genital tract can exhibit a spectrum of a worrisome morphologic features, with polyps occurring during pregnancy being especially pseudosarcomatous. Cytologic atypia has been a recognized feature in these lesions. Patients with a combination of atypical features may have greater recurrent potential. The treatment of choice is local excision. Recurrence may occur if resection is incomplete.<sup>3</sup> To ensure completeness of surgical removal, it is urged that pathologists pay special attention to excision margins.

## References

1. Chirayil SJ, Tobon H. Polyps of the vagina: A clinicopathological study of 18 cases. *Cancer* 1981; 47:2904-7.
2. Ostor AG, Fortune DW, Riley CB. Fibroepithelial polyps with atypical stromal cells (pseudosarcoma botryoides) of vulva and vagina. *Int J Gynecol Pathol* 1988; 7:351-60.
3. Carter J, Elliot P, Russel P. Bilateral fibroepithelial polyp of labium minus with atypical stromal cells. *Pathology* 1992; 24:37-9.
4. Halvorsen TB, Johannesen E. Fibroepithelial polyp of vagina: are they old granulation tissue polyps? *J Clin Pathol* 1992; 45:235-40.
5. Hartmann C-A, Sperling M, Stein H. So called fibroepithelial polyps of the vagina exhibiting an unusual but uniform antigen profile characterized by expression of desmin and steroid hormone receptors but no muscle-specific actin or macrophage markers. *Am J Clin Pathol* 1990; 93:604-8.
6. Mucitelli DR, Charles EZ, Kraus FT. Vulvovaginal polyps. Histologic appearance, ultrastructure, immunocytochemical characteristics, and clinicopathologic correlation. *Int J Gynecol Pathol* 1990; 9:20-40.
7. Nucci MR, Fletcher CDM. Fibroepithelial stromal polyps of vulvovaginal tissue. From the banal to bizarre. *Pathol Case Rev* 1998; 3:151-7.
8. Elliot GB, Reynolds HA, Fidler HK. Pseudosarcoma botryoides of cervix and vagina in pregnancy. *J Obstet Gynaecol Br Cwlth* 1967; 74:728-33.
9. Cachaza JA, Caballero JJJ, Fernandez JA, Salido E. Endocervical polyp with pseudosarcomatous pattern and cytoplasmic inclusions: an electron microscopic study. *Am J Clin Pathol* 1986; 85:633-5.
10. Al-Nafussi AI, Rebello G, Hughes D, Blessing K. Benign vaginal polyp: a histological, histochemical and immunohistochemical study of 20 polyps with comparison to normal vaginal subepithelial layer. *Histopathology* 1992; 20:145-50.