

Adhesion Formation and Intraperitoneal Catheters

M.Şadi YILMAZ¹, Davut GÜVEN¹, Yurdanur SÜLLÜ², Özgür ERDOĞAN¹, İsmail KILICO¹
İdris KOÇAK¹, Cazip ÜSTÜN¹

Samsun, Turkey

OBJECTIVE: Aim of the present study was to determine effect of silicone and polyvinyl chloride in a rat model.

STUDY DESIGN: A randomised blind study was performed using a rat model of laparotomy.

Setting: Surgical Research laboratory in a university medical school.

Intervention(s): Fifty four rats were divided into three groups: Group 1 (n:18), simple laparotomy; and group 2 (n:18) polyvinyl chloride were placed intraperitoneally; Group 3 (n:18), silicone was placed intraperitoneally.

Main outcome measure(s): Three weeks after laparotomy, repeat laparotomy was performed and the adhesions were scored.

RESULT General adhesion scores in groups 2 and 3 were higher than in group 1 ($p < 0.05$). In group 1, none of the rats presented adhesion. The results for groups 2 and 3 were similar.

CONCLUSIONS: The overall adhesions score did not differ significantly between groups 2,3. Silicone and polyvinyl chloride causes adhesion development in rat model.

Key Words: Adhesion, Polyvinyl chloride, Silicone, Animal

Gynecol Obstet Reprod Med; 14:3 (163 - 165)

Introduction

The need to drain has always been a controversial subject in surgery. There are those who believe that all intraperitoneal operations should be drained, those who feel that drainage is useless and those who sit on the fence and insert a drain as a safety valve or perhaps as a sop to their consciences. Their discussions are largely based on personal opinions and the number of drains on the market bear witness to the fact that no one is ideal or suitable for universal use in the wide field of surgery. There are, indeed, a variety of factors which mitigate against the design of an-all purpose drain.¹

Post surgical abdominal adhesions are the leading cause of small bowel obstructions; infertility and abdominal and pelvic pain.^{2,3} Drainage tubes and intraperitoneal catheters, when placed close to injured tissues after abdominal surgery can induce adhesion formation, especially when they remain in the peritoneal cavity for a prolonged period.⁴

The purpose of this experimental study was to compare the adhesion formation from intraperitoneal catheters made of different materials used in surgical practice.

¹Department of Obstetrics and Gynecology and ²pathology Faculty of Medicine Ondokuz Mayıs University, Samsun

Address of Correspondence: Davut Güven
Cumhuriyet Mah. Atatürk Bul. 11. Sok.
No:1 Bahadır Apt. D:6 Atakum, Samsun
dguven@omu.edu.tr
davut_guven@yahoo.com

Submitted for Publication: 25.09.2008

Accepted for Publication: 29.09.2008

Material and Method

Fifty four adult female wistar rats weighting 150-200 gr were randomly assigned to three experimental groups according to the intraperitoneally implanted material; group 1 (n:18) was made simple laparotomy, group 2 (n:18), drain tube from polyvinyl chloride (PVC) and group 3 (n:18), drain tube made from silicone. All procedures were carried out according to the national institutes of health guidelines on laboratory animals and approved by ethical committee of Ondokuz Mayıs University Medical School.

After anesthesia was induced (IM injection of xylazine hydrochloride 5 mg/kg and ketamine hydrochloride 5 mg/kg), a 3 cm midline incision was made on the anterior of the abdominal wall, and the drain like tube was put in the back of the uterus. In the control group closed midline incision was secured to the anterior surface of the fascia with a vicryl 4.0 suture. The small distal edge of the tube was completely covered by the skin. The tubes was 2 cm and 8 Fr standart.

Three months after the initial operation the abdomen was opened. The person scoring the adhesions was blinded to the groups assignment of the animals. The adhesion grade was evaluated according to Blauer's scoring system 0: no adhesions; 1: thin, easily seperable adhesions; 2: thick adhesions limited to one area; 3: thick and widespread adhesions; and 4: thick and widespread adhesions, plus adhesions of viscera to the anterior and/or posterior abdominal walls.

A biopsy of adhesions was performed in some animals in which moderate and severe adhesions were present. In addition, tissue was obtained from some animals when moderate

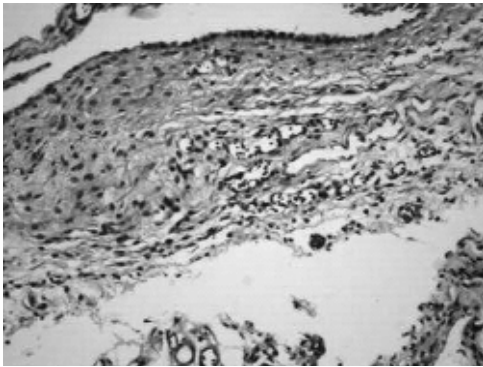


Figure 1: PVC group: Severe inflammation and vascular proliferation were seen in the adhesion (Trichrome x 200)

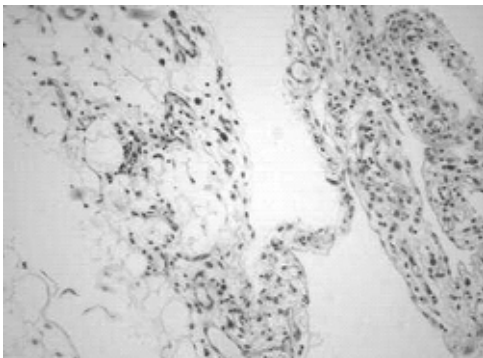


Figure 2: PVC group: Moderate inflammation and vascular proliferation were seen in the adhesion (HE x 100).

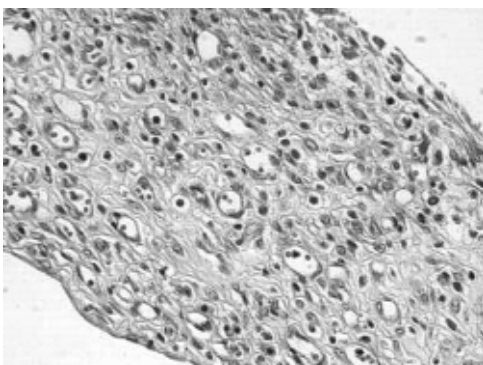


Figure 3: Silicon group: Moderate inflammation and vascular proliferation were seen in the adhesion (HE x 400)

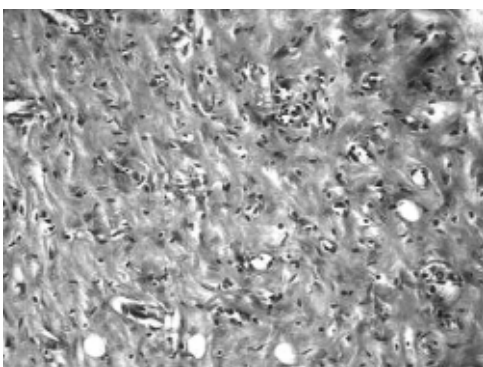


Figure 4: Silicon group: Severe inflammation and moderate vascular proliferation were seen in the adhesion (Trichrome x 200).

and severe adhesions were present. Tissue was removed, fixed in 10% formalin, and stained with hematoxylin and eosin. Histologic analysis evaluated were; degree of inflammation, vascular proliferation, adhesion extent, adhesion density wall (Fig 1,2,3,4).

Student’s test and chi-squared tests were used to compare groups. $p < 0.05$ was defined as statistically significant. Data are expressed as means \pm SEM.

Results

The control group showed the lowest incidence of postsurgical adhesions as compared to polyvinyl chloride and silicone groups. The adhesion scores were $0 \pm 0, 1.44 \pm 0.88, 1.55 \pm 0.52$ in the control group ; the PVC group and the silicone group, respectively (Table 1). Group 1, none of the rats presented adhesions. The results for groups 2 and 3 were similar. Rats of group 2 developed adhesions that were extensive (33.3%) thin (8.7%) degree of inflammation (21.7%), vascular proliferation (21.2%). Group 3 developed adhesions that were extensive (30.9%), thin (9.2%), degree of inflammation (17.4%) vascular proliferation (20.4%). Histopathologically, the grade of the inflammation, vascular proliferation, density of the adhesion and the expansion of the adhesion were scored. The study groups, it has been shown that the study groups had significant amounts of adhesions when compared to the control group ($p < 0.05$). Similar adhesion scores were obtained from PVC and silicone groups and no statistical difference was found between them ($p > 0.05$). (Table 2).

Table 1: Macroscopic assessment of adhesions.

	No of rats	0	1	2	3	4	Mean 1 SEM
Group 1	18	18	0	0	0	0	$0 \pm 0(0.0)$
Group 2	18	2	8	4	3	1	1.44 ± 0.88
Group 3	18	0	4	10	3	1	1.55 ± 0.52

Table 2 : Four criteria for the microscopic assessment of adhesions

	inflammation	Extent	Density	Vascular proliferation
Group 1	0.66 ± 0.50	0.33 ± 0.50	0.33 ± 0.50	0.00 ± 0.00
Group 2	22.33 ± 0.70	2.22 ± 0.66	2.33 ± 0.70	1.77 ± 0.44
Group 3	2.55 ± 0.52	2.55 ± 0.52	2.77 ± 0.44	1.88 ± 0.60

Discussion

Adhesion formation is induced by mechanical injury, ischemia or introduction of foreign materials into the peritoneal cavity. Suggested method for preventing adhesion formation include prophylactic antibiotics, IP instillation of dextran, corticosteroid or nonsteroidal antiinflammatory drugs, and synthetic barrier agents.^{5,6,7}

In the study, we examined the effect of drainage tubes made up of polyvinyl chloride and silicone on adhesion formation. Several reports have demonstrated that the incidence of an adhesion is determined in the 5-7 days after peritoneal trauma takes place, whereas the severity and ex-

tent of adhesions might change over weeks and months.^{8,9,10,11}

We found that PVC and silicone was associated with a greater overall adhesion score.

Adhesions associated with PVC and silicone tended to be thicker and more extensive with the adherent organs. Of the five criteria used in the histologic evaluation, only the degree of inflammatory infiltration at the adhesion site did not seem to differ between the two groups.

This study demonstrates that PVC and silicone causes adhesion development in experimental model. Further studies should be performed in experimental models and an humans to investigate the relative adhesiogenic potential of currently available materials in terms of such clinical implications as infertility and bowel obstruction.

İntraperitoneal Kateterler ve Adezyon Oluşumu

Bu çalışmada amaç rat modeli üzerinde silikon ve polyvinil chlorid'in etkisini belirlemektir.

Laparotomi rat modeli kullanılarak, rastgele kör bir çalışma Tıp Fakültesi Üniversitesi, Cerrahi Araştırma Laboratuvarı'nda yapıldı. 54 rat 3 gruba ayrıldı. Grup 1(n=18), basit laparotomi uygulanan. Grup 2(n=18), intraperitoneal olarak polyvinil chloride yerleştirilen. Grup 3 (n:18), intraperitoneal silikon yerleştirilen. Laparatomiden 3 hafta sonra tekrar laparotomi yapıldı ve adezyonlar skorlandı. Grup 2 ve grup3'ün genel adezyon skorları grup 1'den daha fazlaydı (p<0.05). Grup 1'de adezyon yoktu. Grup 2 ve 3'tekiler benzerdi. Grup 2 ve 3 arasında adezyon skorları arasında önemli bir fark bulunamadı. Rat modelinde silikon ve polyvinil chloride adezyon gelişimine neden olmaktadır.

Anahtar Kelimeler: Adezyon, Polivinil klorit, Silikon, Hayvan

References

1. J.O.Robinson.Surgical drainage :On historical perspec-

tive. Br.J.Surg.1986;vol.73;422-6

2. Dizegera G. The cause and prevention of postsurgical adhesions;a contemporary update.prog Biol Res 1993; 381:1-18
3. Dizegera G. Contemporary adhesions prevention. Fertil Steril 1994;61:219-35
4. Robinson J. Surgical drainage:a historical perspective.Br J Surg 1986;73:422-6
5. Koçak, Ünlü C, Akcam Y, Kayhan Yakın. Rduction of adhesion formation with cross-linked hyaluronic acid after peritoneal surgery in rats. Fertil Steril 1999;72:873-8.
6. Manz. C, la Tendresse C, Sako Y. The detrimental effect of drains on colonic anastomosis:an experimental study. Dis colon rectum 1970;13;17-25.
7. Holtz G. (1985) Current use of ancillary modalities for adhesion prevention. Fertility and Sterility,1985;44,174- 6.
8. Rodgers K. E., Johns D. B. and Girgis W. Reduction of adhesion formation with hyaluronic acid after peritoneal surgery in rabbits. Fertility and Sterility, 1997: 67. 553-8.
9. Burns JW: Preclinical evaluation of seprafilm biore-sorbable membrane. European Journal of Surgery Supplement 1997; 577: 40 -8
10. Johns D.A, Ferland R, Dunn R: initial Feasibility study of a sprayable hydrogel Adhesion barriersystem in patients undergoing laparoscopic overian surgery. Journal American Assoc. Gynecol.Laparasc. 2003;10: 334-8.
11. Metter L, Auedert A, at al: A randomized, prospective, controlled, multicenter clinical trial of sprayable, site -specific adhesion barrier system in patients undergoing myomectomy. Fertility and Sterility 2004; 82: 398-404