

# Non-Hodgkin Lymphoma Presenting as Advanced Ovarian Cancer-Report of Three Cases

Tayfun GÜNGÖR<sup>1</sup>, Serap AKBAY<sup>2</sup>, S. Özlem ALTINKAYA<sup>1</sup>, Mustafa ÖZAT<sup>1</sup>, Ümit BİLGE<sup>1</sup>

Ankara, Turkey

Primary origin for lymphoma is the lymph nodes, spleen and bone marrow. Extranodal sites are involved in more than 30% of the cases. Ovarian involvement by malignant lymphomas is well known as a late manifestation disseminated nodal disease. But, primary ovarian lymphoma and secondary ovarian involvement as initial manifestation of lymphoma are unusual. Clinical data of the three patients with non-Hodgkin lymphoma mimicking advanced ovarian cancer are presented. Preoperative imaging studies revealed pelvic solid masses suggesting an ovarian tumor and Ca-125 levels were elevated. The diagnosis of malignant lymphoma was established from the specimens after exploratory laparotomy. Less than 1% of patients with malignant lymphoma present with an ovarian mass. In the presence of an ovarian tumor, the possibility of lymphoma should be considered, and its clinical and biological signs should be actively sought. Although rarely encountered lymphoma should be included in the differential diagnosis of gynecologic malignancies because of a favorable outcome when properly diagnosed and treated.

**Key Words:** Ovarian cancer, Malignant lymphoma, Pelvic mass

*Gynecol Obstet Reprod Med;15:2 (123-126)*

## Introduction

The primary site of origin for lymphoma is the lymph nodes and other lymphoid tissues such as the spleen and bone marrow; however, in approximately 30% of cases, extra-nodal sites are involved including the female genital tract. Non Hodgkin lymphoma (NHL) presenting as a gynecologic malignancy is exceedingly rare. Involvement of the ovary by malignant lymphoma is well known as a late manifestation of disseminated nodal disease. But primary ovarian lymphoma and secondary ovarian involvement as initial manifestation of lymphoma are unusual.<sup>1</sup>

We present three cases of malignant lymphoma presenting as an advanced ovarian cancer.

## Case Reports

### Case 1

A 38 year-old woman was referred to our hospital for a

<sup>1</sup>Zekai Tahir Burak Women's Health Care Research and Education Hospital, Gynecologic Oncology Department and <sup>2</sup>Pathology Department, Ankara

Address of Correspondence: S. Özlem Altinkaya  
Oğuzlar Mah. 39 Sok. Çağdaş Apt. 3/6  
Balgat, Ankara  
altinkayaozlem@yahoo.com

Submitted for Publication: 05.05.2009

Accepted for Publication: 09.06.2009

pelvic mass. Her gynecological history included cystocele operation three years earlier. On admission she was complaining about fatigue and lower abdominal fullness. Physical examination revealed a voluminous solid mass in left adnexa. Neither liver nor spleen was palpable. Laboratory examinations showed a hypochromic microcytic anemia with hemoglobin of 9.4 g/dl. The serum tumor markers were positive for CA 125: 218 UI/ml (normal range <35 UI/ml) and for CA 15-3: 35 IU/ml (normal range <25 UI/ml), and negative for CA 19-9, AFP, and HCG. Ultrasonography of abdomen and pelvis, and computerized tomography revealed a heterogeneous solid pelvic mass measuring 11x5 cm in left adnexa with lymphadenopathy up to 5 cm within para-aortic region and a minimal peritoneal fluid. Doppler ultrasonography revealed increased vascular flow in the adnexal mass with a pulsatility index of 0.63 and resistance index of 0.50. Mild splenomegaly was also noted. After a blood transfusion, she underwent exploratory laparotomy. The histologic examination of a frozen section led to suspect an ovarian malignant tumor. Surgery was then completed with a total abdominal hysterectomy, bilateral salpingo-oophorectomy, omentectomy, pelvic para-aortic lymph node dissection, and appendectomy. Final histology revealed a non-Hodgkin large B cell lymphoma involving the left ovary. She was consulted to medical oncology and bone marrow examination revealed a malignant B-cell lymphoma. Combined chemotherapy treatment was administered by medical oncology and she is in her second year follow-up.

## Case 2

A 56 year-old woman presented to our hospital with symptoms of abdominal swelling and early satiety. Physical examination revealed approximately 8 cm palpable mass in right adnexa. The patient's review of symptoms was negative for fever, chills, weight loss, night sweats, nausea, vomiting, or bowel or bladder symptoms. She has had diabetes mellitus for 3 years regulated by oral antidiabetic treatment. A computerized tomography of the abdomen and pelvis revealed a solid heterogeneous mass measuring 10x8 cm in right adnexa contiguous with the uterus and extending into the left adnexa. Neither splenomegaly nor hepatomegaly was noted. CA 125 was elevated at 243 UI/ml. Other tumor markers and laboratory findings were within normal limits. Based on these findings, a diagnosis of ovarian cancer was suspected. She underwent exploratory laparotomy. Omental cake and a palpable mass of enlarged lymph nodes in the ileal mesenterium were noted. During surgery, total abdominal hysterectomy, bilateral salpingo-oophorectomy, omentectomy, pelvic para-aortic lymph node dissection, appendectomy, biopsy of large mesenterial lymph nodes and approximately 15 cm ileal resection. The definite pathologic diagnosis was follicular lymphoma. She was consulted to medical oncology and bone marrow examination did not show any evidence of bone marrow involvement with malignant lymphoid cells. Combined chemotherapy treatment was administered by medical oncology and at 9 months since diagnosis, she is feeling well and clinically free from disease.

## Case 3

A 13 year-old girl visited our hospital with complaints of abdominal swelling and fatigue. Imaging studies revealed bilateral solid pelvic tumors, each measuring 12 cm in diameter and multiple enlarged lymph nodes in para-aortic region. Laboratory studies showed elevated levels of serum lactate dehydrogenase (1796 UI/L; normal 240-480) and CA 125 (49 UI/ml; normal <35 UI/ml). At exploratory laparotomy, bilateral adnexal tumors, each measuring approximately 13 cm in size were noted, also there were tumoral implants on omentum and in para-aortic region. The histologic examination of a frozen section led to suspect a malignant ovarian tumor. Therefore, she received optimal de-bulking surgery, including total abdominal hysterectomy, bilateral salpingo-oophorectomy, omentectomy, pelvic and para-aortic lymph node sampling and appendectomy. The final pathologic report revealed mature B cell non-Hodgkin lymphoma (Figure 1 and 2). With advanced immunohistochemical staining, tumor cell markers revealed LCA, CD-20 positive and desmin, vimentin, keratin, CD-34, HMB-45 negative staining. After the postoperative fifth day, her condition worsened. She had nausea, vomiting and elevated serum levels of urea and creatin. Anuria developed on postoperative tenth day and she died of cardiac arrest.

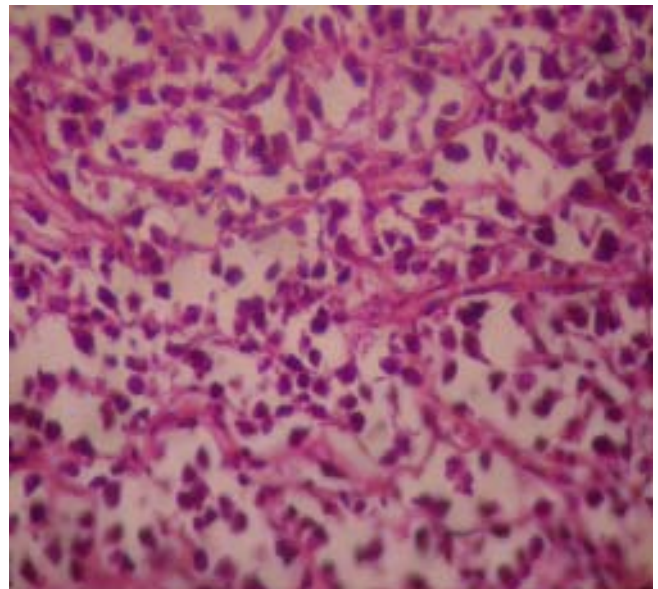
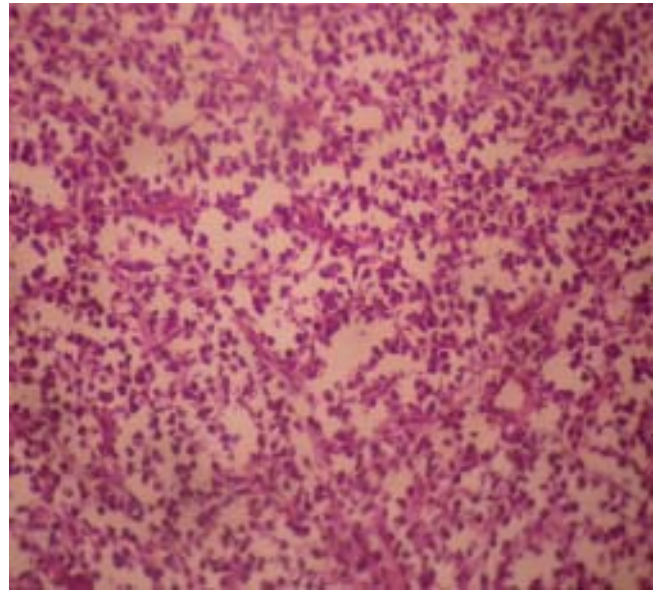


Figure 1 and Figure 2 show B cell malignant lymphoma cells

## Discussion

Non-Hodgkin lymphoma (NHL) involving the gynecological tract is unusual and may cause confusion for the clinician, since its presentation might resemble other, much more frequent tumors. The ovary is the most frequent site for NHL involvement of the gynecological tract. Involvement of the ovary by malignant lymphoma is well known as a late manifestation of disseminated nodal disease. But primary ovarian lymphoma and secondary ovarian involvement as initial manifestation of lymphoma are unusual.<sup>1</sup> Malignant lymphoma is revealed by an ovarian mass in less than 1% of all non-Hodgkin lymphoma, while autopsies performed on patients with NHL show an ovarian enlargement in 7-26%.<sup>2</sup> Primary ovarian lymphoma (POL) is still much rarer and represents 0.5 % of NHL and 1.5 % of all ovarian neoplasms.<sup>3</sup> Lymphoma

may indeed involve the ovary as a primary neoplasm, as an initial clinical manifestation of an occult nodal disease, or that of a widely disseminated systemic lymphoma. Fox et al.<sup>4</sup> have proposed the following stringent criteria for the diagnosis of a POL:

1. At the time of diagnosis, the lymphoma is clinically confined to the ovary, and a full investigation fails to reveal evidence of lymphoma elsewhere. A lymphoma can still be considered as primary if spread has occurred to immediately adjacent lymph nodes or if there has been direct spread to infiltrate immediately adjacent structures.

2. The peripheral blood and bone marrow should not contain any abnormal cells.

3. If further lymphomatous lesions occur at sites remote from the ovary, then at least several months should have elapsed between the appearance of the ovarian and extraovarian lesions.

Applying these strict criteria, the occurrence of POL becomes even more rare than previously mentioned. Furthermore, there is no way to determine definitely whether an ovarian lymphoma is truly primary or an early localized manifestation. Paladugu et al [5] proposed that there should be a disease free interval following treatment of the ovarian lesion by surgery alone. However, in literature, most patients were further treated with chemotherapy with or without radiation.

Having the positive bone marrow biopsy in our case 1, and positive large mesenteric lymph nodes in case 2, it probably can not be considered as a primary ovarian disease although no other signs and symptoms have been detected on further investigation. As our third patient died on postoperative tenth day, and her family did not permit an autopsy, no further investigation could be made. That's why; the question of whether our patient represents a case of a very rare primary ovarian malignant lymphoma or merely represents a case of bilateral ovarian initial manifestation of an occult generalized disease can not be answered.

Reports of malignant lymphoma have documented the association between serosal involvement and elevated CA-125, leading to the speculation that elevated CA-125 levels may be associated with bulky disease.<sup>6,7</sup> To date, lymphoma cells have not been shown to express CA-125; however, mesothelial cells constitutively produce this protein in culture models. Interestingly, this expression is enhanced by the cytokines interleukin-1 $\beta$ , tumor necrosis factor- $\alpha$  and by *Escherichia coli* lipopolysaccharide.<sup>8</sup> A mechanism has therefore been proposed for elevated CA-125 in NHL which postulates cytokine release by lymphoma cells, thereby stimulating serosal mesothelial cells to produce and secrete CA-125.<sup>9</sup> High serum CA-125 levels were found to correlate with mediastinal and/or abdominal involvement, high tumor mass, and effusions, re-

flecting the reaction of mesothelial cells to the tumor.<sup>10</sup> As all of our three cases illustrate, the finding of an elevated CA-125 level in the setting of a pelvic mass should be taken with caution, as the list of differential diagnoses remains long.

In the case of an ovarian mass, few signs suggest the diagnosis of ovarian lymphoma. Most patients are young with a median age of 42-47 years.<sup>2</sup> Fever, emaciation, or night sweats have to be investigated during the patient's interview. Clinical examination will seek a palpable adenopathy, or a liver or spleen infiltration. None of these clinical findings, except a relatively young age and lymphadenopathies in para-aortic region which can be determined in primary ovarian tumors, in imaging studies in cases 1 and 3, were found in our patients. In our case 1, the spleen was not palpable at this time of the diagnosis, and in spite of the fact that ultrasonography revealed a moderate splenomegaly, it was not taken into account during surgery because of the results of the frozen section. The histologic differential diagnosis includes granulose cell tumor, dysgerminoma, small cell carcinoma of hypercalcemic type, granulocytic sarcoma and poorly differentiated surface-epithelial or metastatic carcinoma.<sup>11</sup> The definite diagnosis should be based on clinical information, histologic features, and immunohistochemical profiles.

Ovarian lymphoma was previously believed to have a very poor outcome. This remains true in disseminated lymphomas involving the ovaries. However current reports concluded that primary or localized ovarian lymphomas have a similar outcome compared to patients with other nodal NHL. Prognostic factors in NHL involving the ovary include staging at presentation, acute presentation, and histology other than B-cell lymphomas.<sup>11</sup>

While surgical cytoreduction to a low volume of residual tumor is of proven value in primary epithelial ovarian cancer, there is little information on the outcome of patients with tumors metastatic to the ovary that undergoes cytoreduction. Some groups have reported that such patients benefit from cytoreduction, but debate continues whether the surgical strategy for primary ovarian cancer should be applied to patients with metastatic disease. In the literature, the maximal surgical excision of the tumor does not seem to be associated with a better prognosis for lymphoma. Ayhan et al<sup>12</sup> indicated that, the patients with lymphoma metastatic to the ovaries should be considered separately and the removal of ovarian metastasis palliates symptoms and facilitates the response to treatment and should be applied in patients with lymphoma. However surgery is not the primary mode of therapy for NHL as these tumors are extremely responsive to chemotherapy. In our patients with ovarian NHL, the correct diagnosis allowed the appropriate treatment with the CHOP/rituximab (cyclophosphamide, doxorubicin, vincristine, prednisone) regimen rather than carboplatin/paclitaxel.

In summary, although the gynecologist will rarely experience extra-nodal lymphoma, it should be included in the differential diagnosis of gynecologic malignancies because of a favorable outcome when properly diagnosed and treated.

## İleri Evre Over Kanserini Taklit Eden Non-Hodgkin Lenfoma - 3 Olgu Sunumu

Malign lenfomanın primer başlangıç bölgesi lenf nodları, dalak ve kemik iliğidir. Vakaların % 30'dan fazlasında ekstra-nodal tutulum da görülür. Malign lenfomada over tutulumu dissemine nodal hastalığın geç bulgusu olarak bilinir. Bununla beraber, primer overyan lenfoma ve lenfomanın başlangıç bulgusu olarak sekonder over tutulumu nadirdir. Bu makalede, ileri evre over kanserini taklit eden 3 non-hodgkin lenfoma olgusu sunulmuştur. Preoperatif dönemde olgularda solid pelvik kitle ve artmış serum Ca-125 düzeyleri saptanmıştır. Eksploratif laparotomi sonrasındaki patolojik inceleme sonucunda malign lenfoma tanısı konmuştur. Malign lenfoma hastalarının %1'inden azı overyan kitle ile bulgu verir. Klinikte overyan kitle ile karşılaşıldığında, malign lenfoma olasılığı akılda tutulmalı ve şüphe halinde bu hastalığın klinik ve biyokimyasal bulguları da araştırılmalıdır. Erken tanı ve uygun tedavi ile iyi sonuçlar alındığı düşünülecek olursa, nadiren karşılaşılmasına rağmen, pelvik kitle ayırıcı tanısında malign lenfoma da düşünülmelidir.

**Anahtar Kelimeler:** Over kanseri, Malign lenfoma, Pelvik kitle

## References

1. Yamada T, Iwao N, Kasamatsu H, Mori H. A case of malignant lymphoma of the ovary manifesting like an advanced ovarian cancer. *Gynecol Oncol* 2003 Jul; 90 (1):215-9.
2. Weingertner AS, Hamid D, Roedlich MN, Baldauf JJ. Non Hodgkin malignant lymphoma revealed by an ovarian tumor case report and review of the literature. *Gynecol Oncol* 2004 Dec;95(3):750-4.
3. Dimopoulos MA, Daliani D, Pugh W, Gershenson D, Cabanillas F, Sarris AH. Primary ovarian non-Hodgkin's lymphoma: outcome after treatment with combination chemotherapy. *Gynecol Oncol* 1997 Mar;64(3):446-50.
4. Fox H, Langley FA, Govan AD, Hill AS, Bennett MH. Malignant lymphoma presenting as an ovarian tumour: a clinicopathological analysis of 34 cases. *Br J Obstet Gynaecol* 1988 Apr;95(4):386-90.
5. Paladugu RR, Bearman RM, Rappaport H. Malignant lymphoma with primary manifestation in the gonad: a clinicopathologic study of 38 patients. *Cancer* 1980 Feb; 45(3):561-71.
6. Kutluk T, Varan A, Erbas B, Buyukpamukcu M. Serum Ca-125 levels in children with non-Hodgkin's lymphoma. *Pediatr Hematol Oncol* 1999 Jul-Aug;16(4):311-9.
7. Ozguroglu M, Turna H, Demir G. Usefulness of the epithelial tumor marker CA-125 in Non-Hodgkin's lymphoma. *Am J Clin Oncol* 1999 Dec;22(6):615-8.
8. Allen GW, Forouzannia A, Bailey HH, Howard SP. Non-Hodgkin's lymphoma presenting as a pelvic mass with elevated CA-125. *Gynecol Oncol* 2004 Sep;94(3):811-3.
9. Zeillemaker AM, Verbrugh HA, Hoynck van Papendrecht AA, Leguit P. CA-125 secretion by peritoneal mesothelial cells. *J Clin Pathol* 1994 Mar;47(3):263-5.
10. Lazzarino M, Orlandi E, Klersy C. Serum CA-125 is of clinical value in the staging and follow-up of patients with Non-Hodgkin's Lymphoma: correlation with tumor parameters and disease activity. *Cancer* 1998 Feb 1;82(3):576-82.
11. Perlman S, Ben-Arie A, Feldberg E, Hagay Z. Non-Hodgkin's lymphoma presenting as advanced ovarian cancer- a case report and review of the literature. *Int J Gynecol Cancer* 2005 May-Jun;15(3):554-7.
12. Ayhan A, Guvenal T, Salman MC, Ozyuncu O, Sakinci M, Basaran M. The role of cytoreductive surgery in non-genital cancers metastatic to the ovaries. *Gynecol Oncol* 2005 Aug;98(2):235-41.