

# Focal Endometrial Adenocarcinoma in Atypical Polypoid Adenomyoma of Low Malignant Potential

M. Coskun SALMAN<sup>1</sup>, Ferdi VAİZOĞLU<sup>1</sup>, Alp USUBÜTÜN<sup>2</sup>, Serdar BALCI<sup>2</sup>, M. Sinan BEKSAC<sup>1</sup>

Ankara, Turkey

Atypical polypoid adenomyoma is a rare and benign polypoid lesion of uterus with proliferation of irregular endometrial glands embedded in a smooth muscle stroma. If the lesion contains glands that are sufficiently complex to satisfy the criteria for adenocarcinoma, it is called as atypical polypoid adenomyoma of low malignant potential. Patients most commonly present with abnormal uterine bleeding and more than 90% of patients are premenopausal. Although the lesion is benign, it may occasionally be found to coexist with or to precede endometrial adenocarcinoma. This necessitates a careful management which involves hysterectomy in perimenopausal or postmenopausal patients and hysteroscopy with multiple biopsies in younger women desiring future fertility.

This report describes a perimenopausal woman with atypical polypoid adenomyoma of low malignant potential with focal adenocarcinoma on endometrial biopsy who subsequently underwent hysterectomy in which no residual malignant lesion was found.

**Key Words:** Atypical polypoid adenomyoma, Atypical polypoid adenomyoma of low malignant potential, Endometrial adenocarcinoma

*Gynecol Obstet Reprod Med;15:3 (181 - 183)*

## Introduction

Atypical polypoid adenomyoma (APA) is a rare entity which was first described in 1981 as a benign polypoid lesion of uterus with proliferation of irregular endometrial glands embedded in a prominent cellular smooth muscle stroma.<sup>1</sup> Later, APA of low malignant potential was proposed for the lesions which contain glands that are sufficiently complex to satisfy the criteria for well-differentiated endometrial adenocarcinoma.<sup>2</sup>

Patients most commonly present with abnormal uterine bleeding.<sup>1</sup> More than 90% of patients are premenopausal and half of them are nulliparous.<sup>2</sup> Although the lesion is usually benign in nature, APA may occasionally be found to coexist with or to precede endometrial adenocarcinoma. A literature review indicated an average risk of endometrial carcinoma in women with atypical polypoid adenomyoma of 8.8%.<sup>3</sup> This necessitates a careful evaluation of the lesion without automatically regarding it as being a totally benign entity.

This case report describes a perimenopausal woman with

APA of low malignant potential with focal adenocarcinoma on endometrial biopsy who subsequently underwent hysterectomy in which no residual malignancy was found. Also, the report discusses the management of APA with or without hysterectomy as part of the treatment.

## Case Report

A 47-year-old gravida 2, parity 2 woman admitted to hospital with a complaint of menorrhagia and intermenstrual bleeding. Her past medical history was remarkable for diabetes mellitus and hypertension which were kept under control with oral medications. On her examination, she had an enlarged uterus with multiple leiomyomas. The ultrasonographic evaluation confirmed a 15x7x7 cm uterus with multiple leiomyomas. The ovaries looked normal. She was subjected to an endometrial biopsy which revealed atypical polypoid adenomyoma with low malignant potential (Figure 1). However, a focal well-differentiated endometrial adenocarcinoma could not be excluded (Figure 2). Therefore, a decision of hysterectomy with bilateral salpingo-oophorectomy was made. After preoperative work-up including an internal medicine clearance for her medical problems, the patient underwent a hysterectomy with bilateral salpingo-oophorectomy. The uterus contained leiomyomas with the largest having a diameter of 10 cm. The exploration of the pelvis and abdomen was free of additional abnormalities. The specimen was sent for frozen evaluation in order to perform surgical staging in case of an invasive adenocarcinoma of the endometrium. The frozen section analysis did not reveal residual malignancy within the endometrium. Therefore, no further surgical management was

<sup>1</sup>Department of Obstetrics and Gynecology and <sup>2</sup>Department of Pathology, Hacettepe University Faculty of Medicine, Ankara

Address of Correspondence: Mehmet Coskun Salman  
Hacettepe University Faculty of  
Medicine Department of Obstetrics and  
Gynecology Sıhhiye, Ankara  
csalman@hacettepe.edu.tr

Submitted for Publication: 10.06.2009

Accepted for Publication: 14.08.2009

done. Postoperative course was uneventful and the patient was discharged from hospital after a hospitalization period of 5 days. The final pathological examination showed only remnants of atypical polypoid adenomyoma of low malignant potential without any apparent adenocarcinoma (Figure 3). Patient was asymptomatic during her first post-operative visit 2 months after hysterectomy. She was recommended to have a close follow-up due to her focal, well-differentiated endometrial adenocarcinoma confined only to the endometrium.

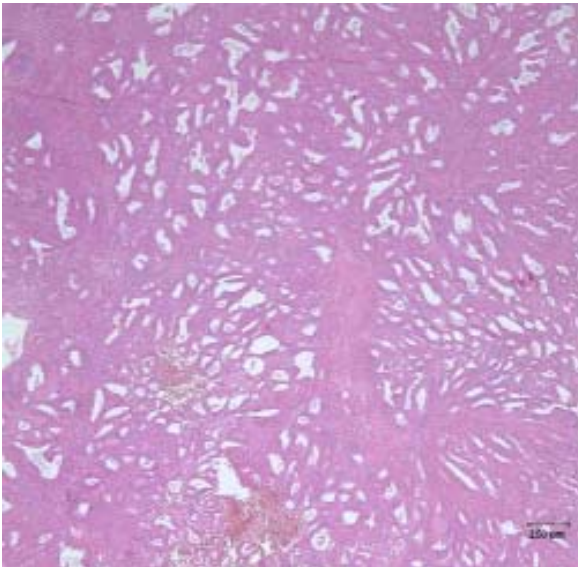


Figure 1: Endometrial curettage revealing endometrial polyp fragments among proliferative endometrium. Endometrial polyp had irregular haphazardly oriented glands within short smooth muscle fascicles showing characteristic features of atypical polypoid adenomyoma.

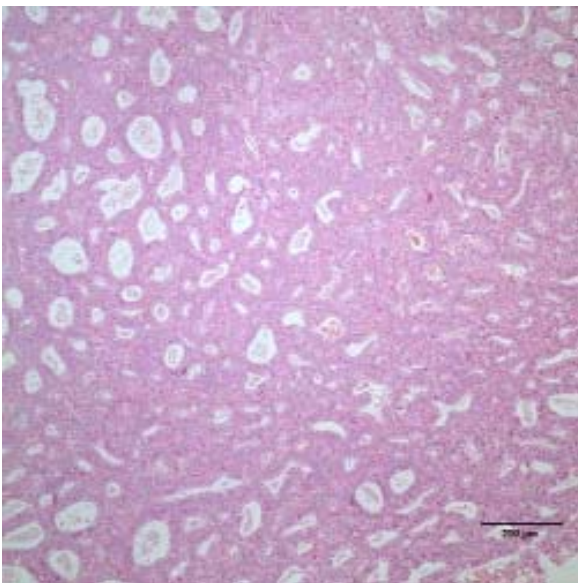


Figure 2: Endometrial biopsy showing a polypoid fragment with glandular crowding. The glands were back-to-back oriented and had complex architecture with minimal atypia and a focal well-differentiated endometrial adenocarcinoma could not be excluded.

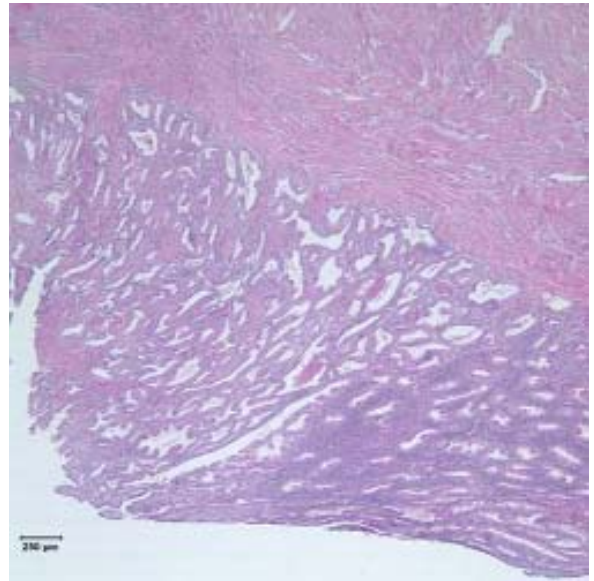


Figure 3: Total abdominal hysterectomy specimen revealing the remnants of atypical polypoid adenomyoma. Near the proliferative endometrium (right side), irregular, haphazardly oriented glands within short smooth muscle fascicles (left side) were observed. There was focal squamous metaplasia. Adenocarcinoma was not observed in hysterectomy specimen.

## Discussion

APA is a rare tumor of endometrium with uncertain histogenesis although either endogenous or exogenous hyperestrogenism was proposed for their development.<sup>4</sup> Even if it represents a benign lesion, careful management is necessary because nearly 9% of patients with APA will have a co-existent endometrial carcinoma either located within the APA or in the adjacent myometrium. Also, almost 1 in 3 patients will have recurrent or residual APA after local excision which indicates a continued risk for the development of malignancy when complete excision of the lesion cannot be guaranteed.<sup>3</sup> The complete removal of the lesion may definitely be achieved by hysterectomy which eliminates future fertility in younger women. Therefore, a hysteroscopic evaluation of the entire endometrial cavity should be done when hysterectomy is not treatment of choice. Such an evaluation should include the removal of residual APA if available, the removal of the endometrium adjacent to APA, the removal of the myometrium underlying APA, and multiple random endometrial biopsies. If any of the specimens is positive for carcinoma, the conservative treatment may be converted into a hysterectomy.<sup>4</sup>

Another major problem in cases with APA is the exclusion of a well-differentiated endometrial carcinoma with myometrial invasion. This may not be of significant importance in older women without any desire for future fertility. Nevertheless, the exclusion of a myoinvasive endometrial carcinoma is of great clinical importance in terms of management when fertility preservation is required. In fact, this issue may

often be encountered since a significant proportion of patients with APA are premenopausal and even nulliparous. Some studies showed that CD-10 immunostaining would be helpful in differentiating between APA and endometrial carcinoma. In those studies, CD-10 was negative in APA while it was positive in carcinoma with myometrial invasion.<sup>5</sup> However, the diagnosis was achieved without any difficulties by using conventional hematoxylen-eosin staining in our case.

On the other hand, the literature also includes patients diagnosed to have APA co-existent with adenocarcinoma of the endometrium.<sup>6,7</sup> The prognosis in such patients was reported to be favorable in general.<sup>7</sup> The term APA of low malignant potential was proposed by some authors if the lesion contains glands that are sufficiently complex to satisfy the criteria for endometrial carcinoma. However, the prognosis is still favorable and fertility preservation is feasible if indicated.<sup>2</sup> The endometrial biopsy which was performed for abnormal uterine bleeding in our patient revealed APA of low malignant potential as well as a focus of well-differentiated endometrial adenocarcinoma. So, her lesion was not only containing glands having criteria of a carcinoma (that is an APA of low malignant potential), but also there was a focus of adenocarcinoma within APA without myometrial invasion (that is a co-existence of APA with adenocarcinoma of the endometrium).

After reviewing the potential risks, a hysterectomy was decided in our patient since she was 47 years old and had multiple large leiomyomas. In view of having a biopsy result indicating the presence of a co-existent endometrial carcinoma, a frozen section evaluation of the uterus was requested during the operation. Neither the frozen section, nor the final pathological evaluation contained any lesions consistent with endometrial carcinoma. Therefore, she was considered to have APA of low malignant potential co-existent with focal well-differentiated endometrial adenocarcinoma.

In conclusion, in cases with APA without fertility desire, the management includes hysterectomy with careful frozen section analysis to reveal any foci of coexistent endometrial adenocarcinoma or differentiate between APA and myoinvasive endometrial adenocarcinoma. If fertility preservation is desired after a diagnosis of APA achieved by blind endometrial biopsy or curettage, the patient should be subjected to hysteroscopy with directed biopsies of any suspicious areas to document the possibility of residual APA or carcinoma. Also, the patient should be informed about the possibility of recurrence of APA as well as the risk of overlooking a malignancy already present.

---

### **Düşük Malignite Potansiyelli Atipik Polipoid Adenomyomda Saptanan Fokal Endometrial Adenokarsinom**

Atipik polipoid adenomyom uterusun nadir görülen, benign polipoid bir lezyonudur ve düz kas stroması içinde proliferen olan irregüler endometrial glandlardan oluşur. Lezyon adenokarsinom kriterlerini taşımaya yetecek derecede kompleks glandlar içerirse düşük malignite potansiyelli atipik polipoid adenomyom şeklinde adlandırılır. Hastalarda en sık başvuru semptomu anormal uterin kanamadır ve %90'dan fazlası premenopozaldır. Lezyon benign olmasına rağmen bazen beraberinde endometrial adenokarsinom bulunabilir veya lezyon adenokarsinoma ilerleyebilir. Bu nedenle dikkatli bir yaklaşım gerekir. Perimenopozal veya postmenopozal hastalarda histerektomi tercih edilirken fertilitate arzusu olan genç hastalarda histeroskopi ve histeroskopik biopsiler tercih edilmelidir.

Burada endometrial biopside düşük malignite potansiyelli atipik polipoid adenomyomda fokal endometrial adenokarsinom saptanan perimenopozal bir hasta sunulmaktadır. Hastaya histerektomi yapılmış ve rezidü malign lezyon saptanmamıştır.

**Anahtar Kelimeler:** Atipik polipoid adenomyom, Düşük malignite potansiyelli atipik polipoid adenomyom, Endometrial adenokarsinom

---

### **References:**

1. Mazur MT. Atypical polypoid adenomyomas of the endometrium. *Am J Surg Pathol* 1981; 5:473-82.
2. Longacre TA, Chung H, Rouse RV, Hendrickson MR. Atypical polypoid adenomyofibromas (atypical polypoid adenomyomas) of the uterus: a clinicopathologic study of 55 cases. *Am J Surg Pathol* 1996; 20:1-20.
3. Heatley MK. Atypical polypoid adenomyoma: a systematic review of the English literature. *Histopathology* 2006; 48:609-10.
4. Di Spiezio Sardo A, Mazzon I, Gargano V, et al. Hysteroscopic treatment of atypical polypoid adenomyoma diagnosed incidentally in a young infertile woman. *Fertil Steril* 2008; 89:456.e9-12.
5. Ohishi Y, Kaku T, Kobayashi H, et al. CD10 immunostaining distinguishes atypical polypoid adenomyofibroma (atypical polypoid adenomyoma) from endometrial carcinoma invading the myometrium. *Hum Pathol* 2008; 39:1446-53.
6. Sugiyama T, Ohta S, Nishida T, Okura N, Tanabe K, Yakushiji M. Two cases of endometrial adenocarcinoma arising from atypical polypoid adenomyoma. *Gynecol Oncol* 1998; 71:141-4.
7. Mittal KR, Peng XC, Wallach RC, Demopoulos RI. Coexistent atypical polypoid adenomyoma and endometrial adenocarcinoma. *Hum Pathol* 1995; 26:574-6.