

Hepatic Hydatid Cyst Mimicing Reflux Esophagitis in Pregnancy: A Case Report

Ahmet Cantuğ ÇALIŞKAN, Hakan AYTAN, Fazlı DEMİRTÜRK

Tokat, Turkey

Hydatid cyst in pregnancy is a rare pathology and its diagnosis and treatment is a complex problem. Cyst hydatid disease can be localized in every organ and frequently seen in Turkey. This report describes the clinical features, evolution and treatment of a pregnant women complaining with upper gastrointestinal symptoms.

A 27-year-old multigravida was admitted to our hospital in her 21st week of pregnancy because of gastroesophageal reflux and dyspeptic complaints. A 7×5×6 cm hepatic hydatid cyst was diagnosed on sonographic examination. The diagnosis was confirmed by an indirect hemagglutination test. The patient refused all of the treatment options and we followed her until the end of pregnancy. Cesarean section was performed because of her previous sections and we removed the hepatic cyst after delivery.

Every physician should be aware of this potential problems because a hydatid cyst can enlarge and rupture during pregnancy and be fatal to both mother and baby.

Key Words: Echinococcus, Pregnancy, Hydatid cyst

Gynecol Obstet Rebrod Med;15:3 (179 - 180)

Introduction

Hydatid cyst disease caused by *Echinococcus granulosus* continues to be a major health problem in endemic areas.¹ It is a zoonotic parasitic disease predominantly affecting the liver, lung and other vital organs.² Canines are the primary host and human disease occurs when the ova are ingested, often as a result of close contact with dogs.

The incidence of hydatid cyst in pregnancy is about 1 in 2000 pregnancies.³ Surgical intervention followed by medical therapy is the definitive treatment with satisfactory outcome.⁴ This report is of a pregnant women who presented with upper gastrointestinal symptoms like epigastric pain, nausea and vomiting, who finally was diagnosed by computed tomography and ultrasonography imaging and serologic tests to have a hydatid cyst of liver.

Case Report

A 27-year-old woman G3P2 was admitted to the hospital

Department of Obstetrics and Gynecology Gaziosmanpaşa University Medicine Faculty, Tokat

*Address of Correspondence: Ahmet Cantuğ Çalışkan
Türkkonut Yapı Kooperatifi yeşilpark
sitesi Kardelen apt.No:58-1 Daire 15
Çayyolu2, Ankara
ahmetcantug@hotmail.com*

Submitted for Publication: 03.02.2009

Accepted for Publication: 15.03.2009

in her 21st week of pregnancy due to regurgitation, heartburn and chronic cough. Ultrasonographic and computed tomography imaging revealed that a 7×5×6 cm, echo-free multilocular cystic mass in the liver. (Figure 1) The diagnosis of hydatid disease was confirmed by an indirect hemagglutination test. Laboratory tests were all within normal limits. The uterus size was appropriate for the gestational age of 21 weeks and it contained a single viable fetus. The treatment options were elucidated to the patient and relevant and they refused all, including percutaneous drainage, laparotomy surgery and medical treatment during pregnancy. In the 39th week of pregnancy cesarean section was performed because of her previous sections. At laparotomy the hepatic cysts were removed. (Figure 2) No postoperative complications occurred.

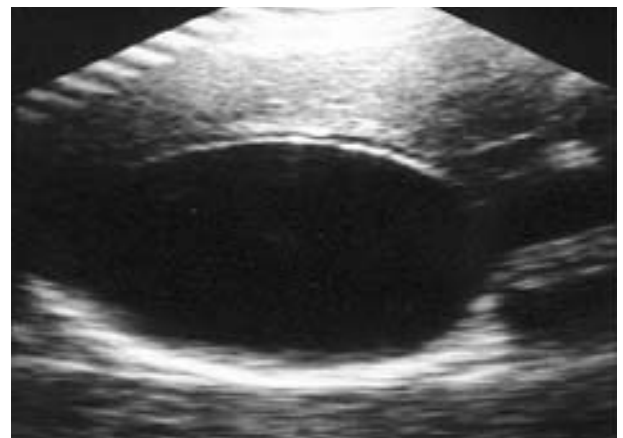

Figure 1: Ultrasonographic image of the hepatic hydatid cyst

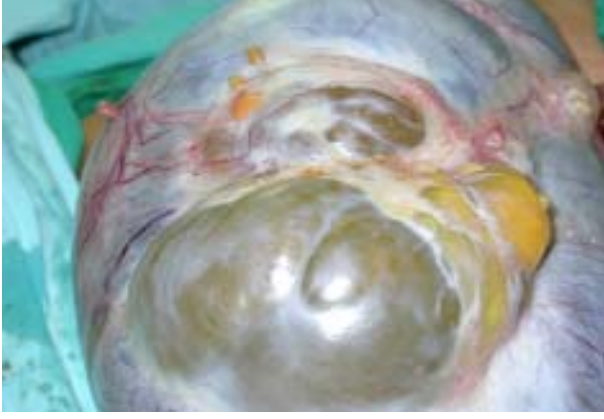


Figure 2: Multilocular posterior surface hydatid cyst of liver at laparotomy

Discussion

Hydatid cyst has a worldwide distribution, with a high prevalence in many countries in the Mediterranean region, the Middle East and far East.⁵ Its incidence is between 1/200000 and 1/300000 in pregnancy.³ Hydatidosis in a pregnant women rarely causes systemic symptoms and its diagnosis is usually established by routine abdominal ultrasound during pregnancy. The clinical manifestations ranges from silent cysts to symptomatic disease. It has a high risk of rupture to the peritoneal cavity, causing anaphylaxis and subsequent problems such as elevating intraabdominal pressure during delivery.⁶ The traditional treatment of hydatid cyst is open surgical procedure but today it is replaced with medical, endoscopic and percutaneous techniques. Medical treatment options like mebendazole and albendazole were not preferred because of the risk of teratogenicity.⁷ There are case reports concerning percutaneous cyst aspiration in pregnant patients but mortality and morbidity rates are not known. During aspiration, systemic reaction, secondary infection or septicemia may be seen. The route of delivery should be determined carefully. Some author usually advise cesarean delivery, while others prefer vaginal delivery.⁷

In conclusion, the patients who have hepatic hydatid cyst can present with a variety of clinical manifestations including gastrointestinal and pulmonary symptoms. In countries where hydatid disease is endemic, obstetricians should be aware of the possibility of the disease and potential for rapid progression and complications during pregnancy. Surgical treatment should be performed in a patient who has been diagnosed during pregnancy because of the cyst complications of premature delivery and potential difficulties during delivery.

As the disease can be fatal, if the treatment is unfeasible,

patients should be closely and carefully monitored during pregnancy.

Gebelikte Reflü Özofajiti Taklit Eden Karaciğer Kist Hidatiği: Olgu Sunumu

Gebelikte hidatik kist nadir görülen tanı ve tedavisi karmaşık olan bir patolojidir. Kist hidatik hastalığı her organda görülebilmektedir ve Türkiye'de sıklığı fazladır. Bu raporda üst gastrointestinal sistem semptomlarıyla gelen gebe kadının klinik belirtileri, hastalık gelişimi ve tedavisi incelenmiştir.

27 yaşındaki multigravid hasta gebeliğinin 21. haftasında gastroözofageal reflü ve dispeptik şikayetlerle hastanemize başvurdu. Sonografik muayenede karaciğerde 7x5x6 cm boyutlarında kist hidatik ile uyumlu görünüm saptandı. Tanı indirekt hemaglutinasyon testi ile doğrulandı. Hastalıkla ilgili gebelikte yapılan tüm tedavi seçenekleri hasta tarafından reddedildi ve gebelik durumu doğuma kadar izlendi. Doğum, daha önceki sezaryen doğumlarından dolayı yine sezaryenle gerçekleşti ve bebek doğurtulduktan sonra karaciğer kist hidatiği çıkarıldı.

Gebelik sırasında kist hidatik büyüyerek rüptüre olabileceğinden, anne ve bebek için ölümcül bir durum yaratabileceğinden tüm doktorlar bu potansiyel tehlike hastalığa karşı dikkatli olmalıdırlar.

Anahtar Kelimeler: Ekinokok, Gebelik, Kist hidatik

References

1. Kammer WS, Schantz PM. Echinococcal disease. Infect Dis Clin N Am 1993;7:605-616.
2. Dede S, Dede H, Caliskan Z, Demir B. Recurrent pelvic hydatid cyst obstructing labor with a concomitant hepatic primary. A case report. J Report Med 2002;47:164-166.
3. Can D, Oztekin O, Oztekin O, Tinar S, Sancı M. Hepatic and splenic hydatid cyst during pregnancy: a case report. Arch Gynecol Obstet 2003; 268:239-240.
4. Kurtoğlu N, Ermendan C, Akdemir R, et al. Interventricular septal hydatid cyst. Echocardiography 2000;17:693-695.
5. Ahmet T, Al-Zaibog M, Allan A, et al. Cardiac echinococcosis causing acute dissection of the left ventricular free wall. Echocardiography. 2002;19:333-336.
6. Rahman MS, Rahman J, Lysikiewicz A. Obstetric and gynaecological presentations of hydatid disease. Br. J. Obstet Gynaecol, 1982;89:665-70.
7. Monterola C, Espinoza R, Munoz S et al. Abdominal echinococcosis during pregnancy: a clinical aspects and management of a serious of cases in Chile. Tropical Doctor 2004;34:321-23.