

# Laparoscopic Management of Ectopic Pregnancy Occurring Ten Years After Tubal Sterilization

Tekin DURUKAN<sup>1</sup>, Mehmet Coşkun SALMAN<sup>1</sup>, Zeliha ATAK<sup>1</sup>, Özgür ÖZYÜNCÜ<sup>1</sup>, Melih VELİPAŞAOĞLU<sup>1</sup>, Alp USUBÜTÜN<sup>2</sup>

Ankara, Turkey

Ectopic pregnancy is still one of the leading causes of maternal mortality. Due to the popularity of elective sterilization procedures, the incidence of ectopic pregnancies following tubal sterilization began to increase in recent years and post-sterilization ectopic pregnancies account more than 10% of all ectopic pregnancies. This case report describes a 41-year-old woman with a diagnosis of an ectopic tubal pregnancy 10 years after laparoscopic tubal sterilization who was successfully managed via laparoscopy. Also, the incidence and risk factors for tubal sterilization failures, mechanisms of failure, and outcomes of failed cases are discussed.

**Key Words:** Tubal sterilization, Ectopic pregnancy, Laparoscopy

*Gynecol Obstet Reprod Med;15:3 (174 - 177)*

## Introduction

Ectopic pregnancy, the implantation of fertilized ovum anywhere other than endometrium, is still one of the leading causes of maternal mortality.<sup>1,2</sup> Most common risk factors for ectopic pregnancy include genital infections, previous ectopic pregnancy, previous tubal surgery, and intrauterine devices.<sup>3</sup> Due to the popularity of elective sterilization procedures in recent years, the incidence of ectopic pregnancies following tubal sterilization began to increase and post-sterilization ectopic pregnancies account more than 10% of all ectopic pregnancies.<sup>4</sup>

The risk of post-sterilization pregnancy persists for years following surgery and method of tubal occlusion and patient's age are important in terms of failure rates.<sup>5</sup> Most failures result from recanalization and establishment of a fistulous opening.<sup>6</sup>

Here, we report a 41-year-old woman who was diagnosed to have an ectopic tubal pregnancy 10 years after laparoscopic tubal sterilization. To best of our knowledge, this is the second latest ectopic pregnancy reported up to date following tubal

sterilization and the first case of proximal tubal ectopic pregnancy occurring 10 years after sterilization.

## Case Report

A 41-year-old, gravida 4, parity 2 woman presented with abdominal pain and vaginal bleeding following an amenorrheic period of approximately 7 weeks. She did not experience menstrual irregularities before and her past medical history was unremarkable except for a laparoscopic interval tubal sterilization via bipolar coagulation which was performed 10 years ago. She had pain and tenderness at right lower quadrant and minimal vaginal bleeding of uterine origin on her examination. Although she had a history of sterilization, a serum human chorionic gonadotropin (hCG) level was studied due to the complaints suggesting ectopic pregnancy. Her serum hCG was greater than 15.000 mIU/ml and transvaginal ultrasonography performed thereafter revealed normal uterus with regular endometrial echo. However, a gestational sac involving a fetus with regular heart beats was detected at right adnexal site (Figure 1). The crown-rump length (CRL) of the fetus was 14 mm which represented a gestational age of 7 weeks and 6 days. Intraabdominal free fluid was absent. Patient was hemodynamically stable and her blood count was in normal limits. She underwent laparoscopy with a preoperative diagnosis of unruptured tubal ectopic pregnancy. On laparoscopy performed 4 hours after her admission, both fallopian tubes were seen to be coagulated at midtubal sites and an unruptured ectopic pregnancy was seen within the proximal portion of the right fallopian tube adjacent to the right cornual region (Figure 2). Laparoscopic bilateral salpingectomy was performed. Pathological examina-

<sup>1</sup>Department of Obstetrics and Gynecology, <sup>2</sup>Department of Pathology Hacettepe University Faculty of Medicine, Ankara

Address of Correspondence: Mehmet Coskun Salman  
Hacettepe University Faculty of  
Medicine Department of Obstetrics and  
Gynecology Sıhhiye, Ankara  
csalman@hacettepe.edu.tr

Submitted for Publication: 21.07.2009

Accepted for Publication: 14.08.2009

tion confirmed preoperative diagnosis (Figure 3). However, recanalization or fistula could not be demonstrated microscopically. The patient was discharged from hospital after an uneventful postoperative course of 24 hours and she is free of any symptoms 6 weeks after the operation.

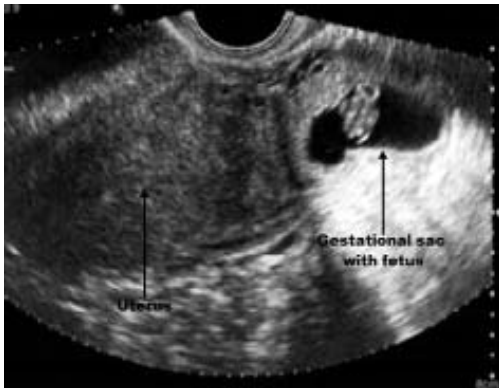

Figure 1. Transvaginal ultrasonography showing right tubal gestational sac involving fetus with a gestational age of 7 weeks and 6 days (crown-rump length of the fetus was 14 mm)

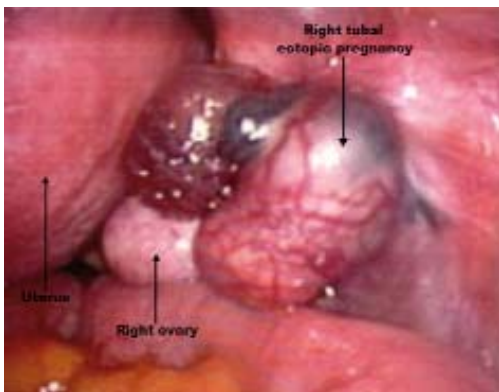


Figure 2. Laparoscopic view of unruptured ectopic pregnancy at right fallopian tube adjacent to the right cornual region

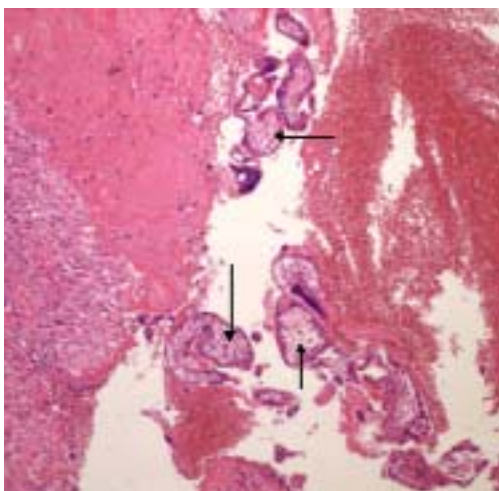


Figure 3: Pathological examination of hematoxylin-eosin stained right salpingectomy specimen showing fallopian tube with chorionic villi (arrows)

## Discussion

Tubal sterilization is a highly popular, safe and effective method of permanent sterilization throughout the world and 700,000 procedures are performed annually in United States. For interval sterilization, one of the most commonly preferred methods is laparoscopic bipolar coagulation.<sup>7</sup> Although the failure risk of the procedure in terms of contraception is extremely low, the risk of ectopic pregnancy is so high in case of a failure. In a multicenter prospective cohort study including 10,685 tubal sterilization procedures using various methods, the rate of failure was 1.3% and among cases with failure 32.9% had ectopic pregnancies mostly (97.9%) in form of tubal ectopic pregnancy.<sup>5</sup> According to the same study, the 10-year cumulative probability of ectopic pregnancy for all methods of tubal sterilization was reported to be 7.3 per 1000 procedures. However, the highest failure risk was associated with the method of bipolar coagulation in which the probability of failure was 17.1 ectopic pregnancies per 1000 procedures. The authors state that the fallopian tubes should be coagulated sufficiently in order to decrease the risk of pregnancies after bipolar coagulation.<sup>5</sup>

The patient's age at the time of sterilization was also documented to impact the risk of ectopic pregnancy after tubal sterilization. The probability of ectopic pregnancy was greater for women sterilized before 30 years of age than for older women especially when the method was bipolar coagulation. Women sterilized via bipolar coagulation before the age of 30 had a 10-year cumulative probability of ectopic pregnancy of 31.9 per 1000 procedures.<sup>5</sup> Our case underwent interval laparoscopic tubal sterilization using bipolar coagulation when she was 31 years.

Most of the ectopic pregnancies occur more than one year after tubal sterilization.<sup>8</sup> Furthermore, in a woman with a history of tubal sterilization, the risk of gestation to be ectopic is much higher if it occurs more than 2 years after sterilization.<sup>9</sup> Ectopic pregnancy may also be encountered even many years after the sterilization procedure. In fact, compared to first 3 years following sterilization, the cumulative probability of ectopic pregnancies was reported to be higher afterwards (2.0 vs. 5.3 per 1000 procedures). Also, the annual rate of ectopic pregnancy was also higher in the 4th through 10th years after sterilization (0.8 vs. 0.7 per 1000 woman-years). In women who underwent bipolar coagulation, the cumulative probabilities of ectopic pregnancy in the first 3 years and thereafter were 3.3 per 1000 procedures and 13.8 per 1000 procedures, respectively.<sup>5</sup> The present case was diagnosed 10 years after sterilization and according to our literature review this is the second latest ectopic pregnancy reported up to date following tubal sterilization. The first case was a 37-year-old woman with a history of tubal sterilization 10 years earlier who was diagnosed to have a twin ectopic ovarian pregnancy.<sup>10</sup> Also,

the present case is the first case of tubal ectopic pregnancy occurring 10 years after tubal sterilization.

The probable explanation for ectopic pregnancy after tubal sterilization is recanalization or formation of a tubo-peritoneal fistula where sperm can pass through to reach the oocyte, but the fertilized ovum cannot.<sup>6</sup> Therefore, implantation occurs in the distal tubal segment. However, the implantation was in proximal tubal segment in our patient without any demonstrable recanalization or fistula.

In cases with ectopic pregnancy, the diagnosis may be delayed due to the history of sterilization. This may be associated with increased risk of morbidity and even mortality since the probability of tubal rupture increases if diagnosis delays.<sup>8</sup> Ectopic pregnancy was diagnosed within a few hours in our patient and laparoscopic exploration was done 4 hours after her admission to emergency ward. She was successfully treated before tubal rupture and possible hemodynamic instability.

As a conclusion, although rare, ectopic pregnancy should always be considered in reproductive-aged women presenting with pelvic-abdominal pain and vaginal bleeding after an amenorrheic period even if they had undergone tubal sterilization many years before. Morbidity and mortality may effectively be reduced with timely diagnosis and therapeutic interventions performed before tubal rupture. Women willing to undergo tubal sterilization should be counseled about the failure rates and informed about the symptoms of ectopic pregnancy. In addition, women younger than 30 years of age may be offered to try alternative methods of contraception prior to permanent sterilization.

### **Tubal Sterilizasyondan On Yıl Sonra Oluşan Ektopik Gebeliğin Laparoskopik Yönetimi**

Ektopik gebelik halen maternal mortalitenin önde gelen nedenlerinden birisidir. Elektif sterilizasyon operasyonlarının popülaritesi nedeniyle tubal sterilizasyon sonrası oluşan ektopik gebeliklerin insidansı son yıllarda artmaya başlamıştır ve sterilizasyon sonrası oluşan ektopik gebelikler tüm ektopik gebeliklerin %10'dan fazlasını oluşturmaktadır. Bu vaka sunumunda

laparoskopik tubal sterilizasyon işleminden 10 yıl sonra ektopik tubal gebelik tanısı konan ve laparoskopi ile başarıyla tedavi edilen 41 yaşındaki bir hastadan bahsedilmektedir. Ayrıca tubal sterilizasyon işleminin başarısızlık sıklığı ve bununla ilgili risk faktörleri, başarısızlığın oluşma mekanizmaları ve ilgili vakaların sonuçları da tartışılmıştır.

**Anahtar Kelimeler:** Tubal sterilizasyon, Ektopik gebelik, Laparoskopi

### **References**

1. Goldner TE, Lawson HW, Xia Z, Atrash HK. Surveillance for ectopic pregnancy, United States, 1970-1989. *MMWR CDC Surveill Summ* 1993; 42:73-85.
2. Ümit Göktolga. Ectopic Pregnancy. *Turkiye Klinikleri J Surg Med Sci* 2006; 2:6-12.
3. Ankum WM, Mol BW, Van der Veen F, Bossuyt PM. Risk factors for ectopic pregnancy: a meta-analysis. *Fertil Steril* 1996; 65:1093-9.
4. Chakravarti S, Shardlow J. Tubal pregnancy after sterilization. *Br J Obstet Gynecol* 1975; 82:58-60.
5. Peterson HB, Xia Z, Hughes JM, Wilcox LS, Tylor LR, Trussell J. The risk of ectopic pregnancy after tubal sterilization. U.S. Collaborative Review of Sterilization Working Group. *N Engl J Med* 1997; 336:762-7.
6. Cheng MC, Wong YM, Rochat RW, Ratnam SS. Sterilization failures in Singapore: an examination of ligation techniques and failure rates. *Stud Fam Plann* 1977; 8:109-15.
7. ACOG practice bulletin. Benefits and risks of sterilization. *Int J Gynecol Obstet* 2003; 83:339-50.
8. Shah JP, Parulekar SV, Hinduja IN. Ectopic pregnancy after tubal sterilization. *J Postgrad Med* 1991; 37:17-20.
9. Chi IC, Potts M, Wilkens L. Rare events associated with tubal sterilizations: an international experience. *Obstet Gynecol Surv* 1986; 41:7-19.
10. Ansari SM, Nessa L, Saha SK. Twin ectopic pregnancy 10 years after permanent sterilization. *Australas Radiol* 2000; 44:107-8.