

Harlequin Ichthyosis: A Case Report

Yetkin KARASU, T. Tuyan İLHAN, R. Sinan KARADENİZ, Orhan GELİŞEN

Ankara, Turkey

Harlequin ichthyosis is a severe and usually fatal congenital keratinization disorder. Although it has many characteristic findings on prenatal ultrasound such as a wide gaping mouth, intrauterine growth retardation, short limbs, joint contractures, edema of the hands and feet and cloudy amniotic fluid, most of the time it is diagnosed at birth. In this case report we summarize a patient who delivered a baby with Harlequin ichthyosis.

Key Word: Harlequin ichthyosis, Prenatal diagnosis

Gynecol Obstet Reprod Med;15:3 (165 - 167)

Introduction

Harlequin ichthyosis (HI) is a severe and usually fatal congenital keratinization disorder with autosomal recessive inheritance. We report a case of HI, which remained undiagnosed until 36 weeks' gestational age and complicated with premature contractions and polyhydramnios.

Case Report

32-year-old woman, gravida 3 and para 2 admitted to the emergency unit of our hospital with complaints of back and labor pains at 36th weeks of her pregnancy. She hospitalized to the labor unit with the diagnosis of preterm labor and polyhydramnios. There was no history of delivering malformed baby in any other member of her family. There was no history of consanguineous marriage. On examination her general condition was stable and she was having mild uterine contractions. After she was accepted to the labor unit the patient examined vaginally by second year resident. He noted that the cervix dilated 4 cm, effaced 60% but there was an abnormality of amniotic membranes. The patient was evaluated with chief gynecologist and it was noted that there was abnormal findings on fetal head instead. On manual vaginal examination

there were fissures and map like plates on fetal head skin. Limited ultrasonographic examination (amniotic fluid index, fetal biometry, fetal cardiac activity, fetal presentation, placental position was noted) was normal except polyhydramnios. Prepartum diagnosis of this condition could not be made. Fetus was externally monitored. At the 15th minute of NST examination, late decelerations and abnormal vaginal bleeding began. Patient was delivered with cesarean section and a baby was born with harlequin ichthyosis. The female baby was born alive at the 36th week of the mother's third pregnancy, her birth weight was 3000g and her length was 50 cm. Baby was handed over to paediatrician. It was covered with thick, hard armour like plates of cornified skin separated by deep fissures (figure 1). The infant had characteristic features typical for HI; ectropion, eclabion, a distorted, flattened nose and low set dysplastic ears (figure 2). There was flexion deformity of all joints of the limbs (figure 3).

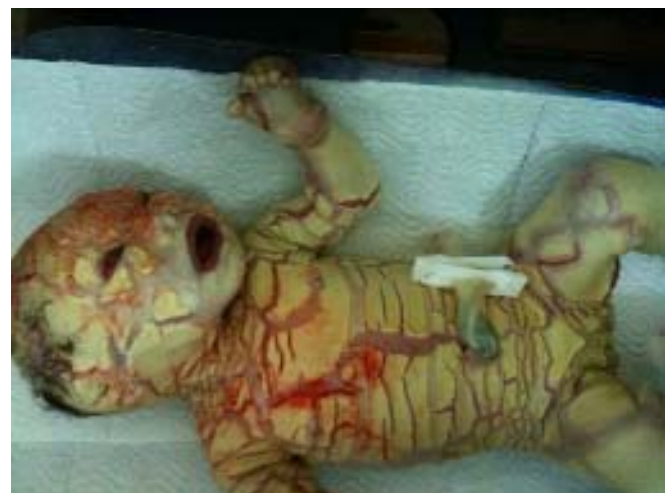

Figure 1: skin features of HI

Etilik Zübeyde Hanım Maternity and Women's Health Academic and Research Hospital, Ankara

Address of Correspondence: R. Sinan Karadeniz
Etilik Zübeyde Hanım Maternity and
Women's Health Academic and Research
Hospital Ankara
sinankaradeniz@gmail.com

Submitted for Publication: 22.10.2009

Accepted for Publication: 23.11.2009

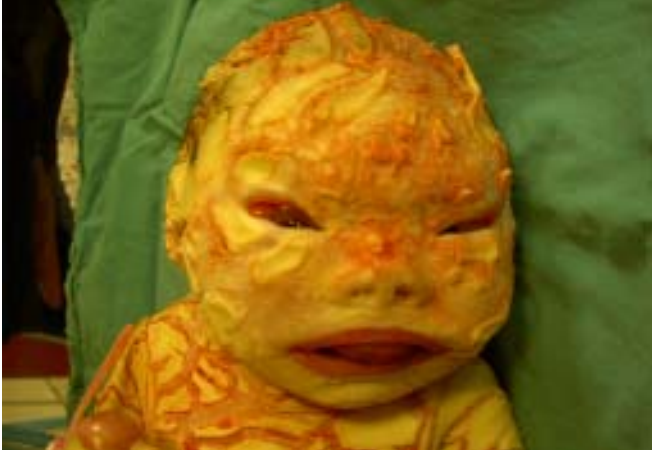

Figure 2: facial features of HI

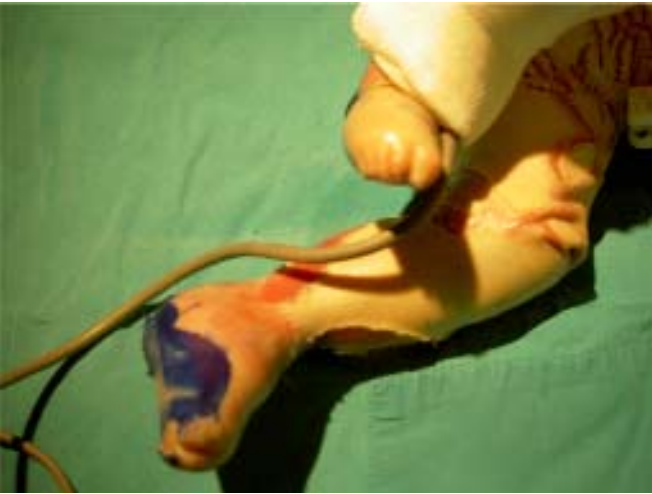


Figure 3: flexion deformities

Discussion

Harlequin ichthyosis (HI) is a severe and usually fatal congenital keratinization disorder with autosomal recessive inheritance.¹ Mutations in the ABCA12 (ATP-binding cassette, sub-family A (ABC1), member 12) gene cause harlequin ichthyosis. The ABCA12 gene provides instructions for synthesis of a protein that is essential for the normal development of skin cells. This protein plays a major role in the transport of fats (lipids) in the outermost layer of skin (the epidermis).^{2,3} The principal signs suggestive of harlequin fetus are: absence of typical ear morphology, atypical facial dysmorphism, large open mouth, absence of typical nasal morphology, partitioned cystic formations in front of the eyes, thick skin, minimal fetal movement with stiff limbs in a semiflexed position, limb anomalies with hypoplastic fingers and toes and short phalanges, clubfoot, shriveled hands that do not open, hyperchogenic amniotic fluid, and an absence of associated visceral anomalies.

For more than 20 years, prenatal diagnosis of HI had been

performed by fetal skin biopsy and electron microscopic observation during the later stages of pregnancies at 19-23 weeks estimated gestational age.^{2,3,4} Prenatal consultation of the parents with effected child by an experienced ultrasonographer is critical. As in our case most of the patients can not be diagnosed until birth and result is shocking both for the parents and the care givers. Prenatal diagnosis of HI is very difficult even for experienced centers. In our case, the patient was followed with regular visits. She was directed to detailed ultrasonography at 20th week of gestation. Three additional USG examinations were performed in the 24th, 30th and 33th weeks of gestation. No abnormality was reported.

A wide gaping mouth, protruding tongue, intrauterine growth retardation, short limbs, joint contractures, edema of the hands and feet and cloudy amniotic fluid are characteristic findings of HI on prenatal ultrasound.^{5,6} Three dimensional ultrasonography may give information about facial and skin features associated with the condition. As in our case if the cervix dilated enough skin features of the disease can be palpated but this usually means that it is quite late for diagnosis. Even with 3D ultrasonography HI is very rare to remember (OMIM#242500) and both ultrasonographers and obstetricians may easily skip the diagnosis.

Prenatal diagnosis may also be important for transfer of the patient to a center with better newborn care. Even in experienced new born units these babies' outcome is poor. In this case baby was stil alive after ten days but there were difficulties about oral feeding (figure 4).

In conclusion we summarized this case to emphasize that HI is a very rare disease which is hard to diagnose prenatally even with regular prenatal visits and ultrasound examinations.

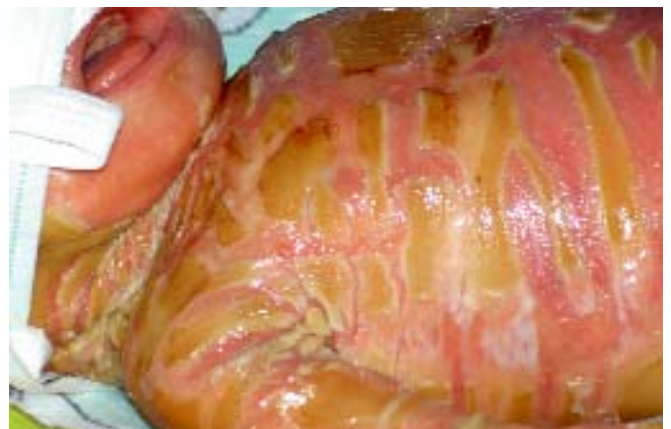

Figure 4: skin lesions after ten days

Harlequin İktiyozis: Bir Olgu Sunumu

Harlequin iktiyozis çok ciddi ve genellikle ölümcül seyreden bir keratinizasyon bozukluğudur. Prenatal ultrasonografide geniş

açık ağız, intrauterin gelişme geriliği, kısa kol ve bacaklar, eklem kontraktürleri, el ve ayaklarda ödem ve hiperekojen amniotik sıvı gibi karakteristik bulgular olsa da çoğu olgu doğumda tanı alır. Bu olgu sunumunda harlequin iktiyozis hastası bebek doğuran bir hasta ele alınmıştır.

Anahtar Kelimeler: Harlequin İktiyozis, Prenatal Tanı

References:

1. Choate KA, Williams ML, Elias PM, Khavari PA (1998) Transglutaminase 1 expression in a patient with features of harlequin ichthyosis: case report. *J Am Acad Dermatol* 38(2 Pt 2):325-329
2. Blanchet-Bardon C, Dumez Y, Labbe' F, et al. Prenatal diagnosis of harlequin fetus. *Lancet* 1983;I(8316):132.
3. Akiyama M, Nakagiri-Sugiyama Y, Sakai K, 2005. Mutations in lipid transport ABCA12 in harlequin ichthyosis and functional recovery by corrective gene transfer. *J Clin Invest* 115: 1777-1785.
4. Akiyama M, Suzumori K, Shimizu H. Prenatal diagnosis of harlequin ichthyosis by the examinations of keratinized hair canals and amniotic fluid cells at 19 weeks' estimated gestational age. *Prenat Diagn* 1999;19:167-71.
5. Berg C, Geipel A, Kohl M, et al. 2003. Prenatal sonographic features of Harlequin ichthyosis. *Arch Gynecol Obstet* 268: 48-51.
6. Bongain A, Benoit B, Ejnes L, Lambert JC, Gillet JY. 2002. Harlequin fetus: three-dimensional sonographic findings and new diagnostic approach. *Ultrasound Obstet Gynecol* 20: 82-85.