

# Cystic Hygroma and Monosomy X

M. Aykut ÖZEK<sup>1</sup>, Mert TURĞAL<sup>1</sup>, Özgür ÖZYÜNCÜ<sup>1</sup>, M. Sinan BEKSAÇ<sup>1</sup>

Ankara, Turkey

Cystic hygroma is a congenital malformation of the lymphatic system. They are associated with chromosomal abnormalities and major structural anomalies. We describe a case of cystic hygroma associated with monosomy X and termination of pregnancy at 14 weeks of gestation.

**Key Words:** Cystic hygroma, Monosomy X, Prenatal diagnosis

Gynecol Obstet Reprod Med 2013;19:34-35

## Introduction

The association between cystic hygroma and monosomy X is well defined. This relationship is especially strong when detected in second trimester. Most common chromosomal abnormalities associated with cystic hygroma are trisomy 21, monosomy X and trisomy 18.<sup>1</sup> With this case; we aimed to re-demonstrate this situation.

## Case Report

Twenty-three year-old woman with an obstetrical history of two losses (first at 19 weeks of gestation and the second at 5 weeks) admitted to clinic. Because of her recurrent abor-

tuses, a work up was performed. Classical mutations for thrombophilia were normal but her homocysteine level was high. The parents were not related. Karyotype analyses of both of them were proved normal. There was no family history of any chromosomal abnormality. During the initial ultrasound assesment at 8 weeks of gestation, vanished twin phenomenon was noted. At 14 weeks; a large, septated cystic hygroma and fetal hydrops detected (Figures 1A and 1B). After genetic counselling the parents elected to have a fetal karyotype and CVS performed. Karyotype analysis revealed the result of monosomy X. The parents decided to terminate the pregnancy and after termination of pregnancy, cystic hygroma behind the neck of the fetus was observed (Figure 1C).

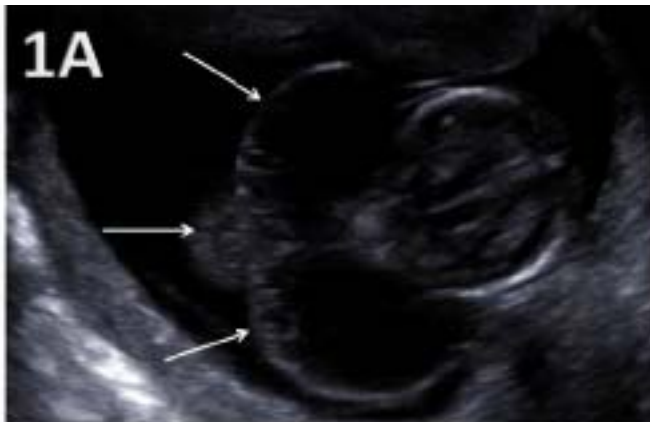

Figure 1A: Ultrasound examination and macroscopic features of the affected fetus A: White arrows indicating septated cystic hygroma behind the neck of the fetus

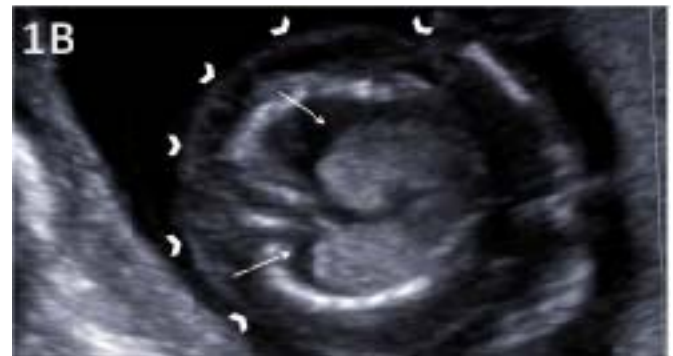

Figure 1B: Arrowheads indicating skin edema and the arrows indicating pleural effusion

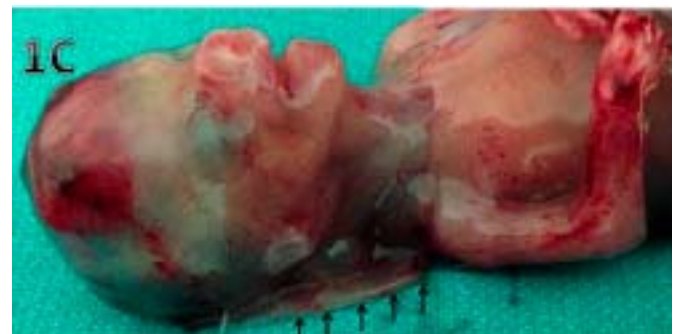


Figure 1C: Black arrows indicating cystic hygroma at the posterior neck region of the fetus

<sup>1</sup> Hacettepe University Faculty of Medicine, Department of Obstetrics and Gynecology, Ankara

Address of Correspondence: Aykut Özek  
Department of Obstetrics and Gynecology  
Hacettepe University Faculty of Medicine  
Sıhhiye, Ankara  
derman@hacettepe.edu.tr

Submitted for Publication: 03. 02. 2013

Accepted for Publication: 15. 04. 2013

## Discussion

Cystic hygroma is a congenital malformation of the lymphatic system. It is an anomaly of the lymphatic drainage into the venous system, which leads to the accumulation of lymph in the jugular lymphatic sacs of the cervical region. They can be nonseptated or septated. Approximate population incidence of septated or nonseptated cystic hygromas is about 1 in 100 fetuses and the prevalence of septated cystic hygromas is 1 in 285 fetuses.<sup>1,2</sup>

Cystic hygromas are usually detected early in pregnancy. They consist of single or multilocular fluid-filled sacs extending from posterior neck.<sup>3</sup> They can also extend through the entire fetus. The distinguishing features of cystic hygromas from increased nuchal translucency are that they tend to be larger, more likely to contain multiple septae and extend through the entire length of the fetus.<sup>1</sup>

Sixty percent of cystic hygromas are associated with aneuploidy.<sup>4</sup> First-trimester cystic hygromas are often associated with trisomies, whereas second trimester cystic hygromas are often associated with Monosomy X.<sup>5</sup> Chromosomal abnormalities seem to be more frequent in septated rather than nonseptated cystic hygromas.<sup>6</sup> Most common chromosomal abnormalities associated with cystic hygroma are trisomy 21, monosomy X and trisomy 18.<sup>1</sup>

When detected in first trimester, about one third of euploid fetuses with septated cystic hygromas have major structural anomalies.<sup>1,7</sup> Among these, cardiac malformations including hypoplastic left heart and coarctation of aorta are the most common ones.

Main differential diagnosis of the cystic hygroma includes neural tube defects, such as a posterior encephalocele or cervical meningocele and cystic teratoma or hemangioma. These diagnoses can usually be excluded on high resolution transvaginal ultrasonography.

The initial obstetric management of fetal cystic hygroma should include fetal karyotyping, ultrasonographic fetal anatomic evaluation (genetic sonogram), fetal echocardiography and serial assessment of fetal status.

The prognosis and fetal outcome is largely dependent on the size of the cystic hygroma; provided that the karyotype is normal and there are no structural anomalies. Large cystic hygromas are usually associated with hydrops and have poor prognosis.<sup>4</sup>

Monosomy X is characterized with loss of part or all of an X chromosome. The missing chromosome is usually the paternal one. It is the only monosomy compatible with life. Most of the conceptuses with this syndrome end up with first trimester abortus (more than 98 percent).<sup>4</sup> Also it is the most

common aneuploidy in abortuses. The prevalence is 1 in 5000 livebirths.<sup>8</sup> Turner syndrome is not associated with advanced maternal age and have different pathogenesis.

Abnormal sonographic findings suggestive of monosomy X are cystic hygroma (usually large, septated and when detected especially in the second trimester), fetal hydrops, cardiac malformations and short femur.<sup>5</sup>

Genetic counselling should be given to the parents because termination of pregnancy may be elected.

---

## Kistik Higroma ve Monozomi X

Kistik higroma, lenfatik sistemin konjenital bir malformasyonu. Kistik higromalar, kromozomal anomaliler ve majör konjenital anomalilerle ilişkilidir. Bu vaka sunumunda, monozomi X ile ilişkili olan ve gebeliğin 14. haftasında sonlandırılan bir kistik higroma olgusunu sunmakta ve literatürü gözden geçirmektediriz.

**Anahtar Kelimeler:** Kistik higroma, Monozomi X, Prenatal tanı

---

## References

1. Malone FD, Ball RH, Nyberg DA, Comstock CH, Saade GR, Berkowitz RL, Gross SJ, Dugoff L, Craigo SD, Timor-Tritsch IE, Carr SR, Wolfe HM, Dukes K, Canick JA, Bianchi DW, D'Alton ME: First-trimester septated cystic hygroma: Prevalence, natural history, and pediatric outcome. *Obstet Gynecol* 2005;106:288-294.
2. Podobnik M, Singer Z, Podobnik-Sarkanji S, Bulic M: First trimester diagnosis of cystic hygromata using transvaginal ultrasound and cytogenetic evaluation. *J Perinat Med* 1995;23:283-291.
3. Cunningham FG, Williams JW: *Williams obstetrics*. New York, McGraw-Hill, Medical Pub. Division, 2010,
4. Cunningham FG, Williams JW: *Williams obstetrics*, ed 23rd. New York, McGraw-Hill Medical, 2010.
5. Bronshtein M, Zimmer EZ, Blazer S: A characteristic cluster of fetal sonographic markers that are predictive of fetal turner syndrome in early pregnancy. *Am J Obstet Gynecol* 2003;188:1016-1020.
6. Rosati P, Guariglia L: Prognostic value of ultrasound findings of fetal cystic hygroma detected in early pregnancy by transvaginal sonography. *Ultrasound Obstet Gynecol* 2000;16:245-250.
7. Graesslin O, Derniaux E, Alanio E, Gaillard D, Vitry F, Quereux C, Ducarme G: Characteristics and outcome of fetal cystic hygroma diagnosed in the first trimester. *Acta Obstet Gynecol Scand* 2007;86:1442-1446.
8. Sybert VP, McCauley E: Turner's syndrome. *N Engl J Med* 2004;351:1227-1238