

Meckel Gruber Syndrome- A Case Report And Review of Literature

Sümeýra NERGİZ¹, Selda DEMİRCAN SEZER¹, Sündüz Özlem ALTINKAYA¹, Mert KÜÇÜK¹, Hasan YÜKSEL¹

Aydın, Turkey

Meckel-Gruber syndrome (MGS) is a lethal autosomal recessive disorder. MGS is thought to be caused by ciliary dysfunction. The worldwide incidence of MGS varies from 1 in 13 250 to 1 in 140.000 live births. MGS is characterized by three main symptoms: central nervous system (CNS) malformations, tetramelic postaxial polydactyly and cystic renal dysplasia with associated fibrocystic changes of the liver, pancreas and epididymis. Here a case of MG syndrome, diagnosed in early weeks of gestation was reported.

Keywords: Meckel gruber syndrome, Ultrasonography, Prenatal diagnosis

Gynecol Obstet Reprod Med 2014;20:175-177

Introduction

Meckel Gruber syndrome (MGS) was first described in 1822 by Meckel¹ and thereafter in 1934 by Gruber.² It is a lethal autosomal recessive disorder characterized by anomalies of the central nervous system (CNS) resulting in mental retardation, cystic dysplasia of the kidneys, and malformations of the hands and feet.^{3,4} Although numerous abnormalities associated with MGS were previously reported in the literature, Dandy-Walker malformation⁵⁻⁷ occipital encephalocele, holoprosencephaly, agenesis of the corpus callosum, hydrocephalus,⁸ microcephaly, intrauterine growth retardation (IUGR), single umbilical artery, cardiovascular defects, cleft palate,^{9,10} several genital abnormalities,^{6,9,10} and oligohydramnios^{5,10} are the most well known. Hepatic periportal fibrosis [7] were also noted in some cases. The worldwide incidence of MGS varies from 1 in 13 250 to 1 in 140.000 live births.¹¹ The condition has a reported incidence of 1:9000 births in Finland;¹² in the UK, it is estimated to be 1:140.000.¹³ Here a case of MGS, diagnosed in early weeks of gestation was reported.

Case Report

A 32-year-old woman, G4 P1 A2, was referred to Adnan Menderes University, Faculty of Medicine, Obstetrics and Gynecology Department at 15 weeks of gestation for the diagnosis of bilateral polycystic kidneys. She had no consan-

guinity with her husband but family history revealed that the previous two pregnancies were affected with polydactyly and bilateral polycystic kidneys (1 female, 1 male) and diagnosed prenatally as MGS. These pregnancies was terminated in the second trimester and the pathological examination confirmed the diagnosis. Only in her first pregnancy, she gave birth to a healthy newborn.

In her ostetric follow up, first trimester Down syndrome screening test had been performed at another center and had revealed increased risk (1/199) of Down syndrome. Further investigation tests for karyotyping (cordocentesis, amniocentesis) were offered but patient denied. Detailed ultrasonographic examination revealed bilateral polycystic kidneys, ventriculomegaly, encephalocele and polydactyly (Figure 1). The family was counseled for recurrent MGS and a termination of pregnancy was carried out at the 16th week of the pregnancy.

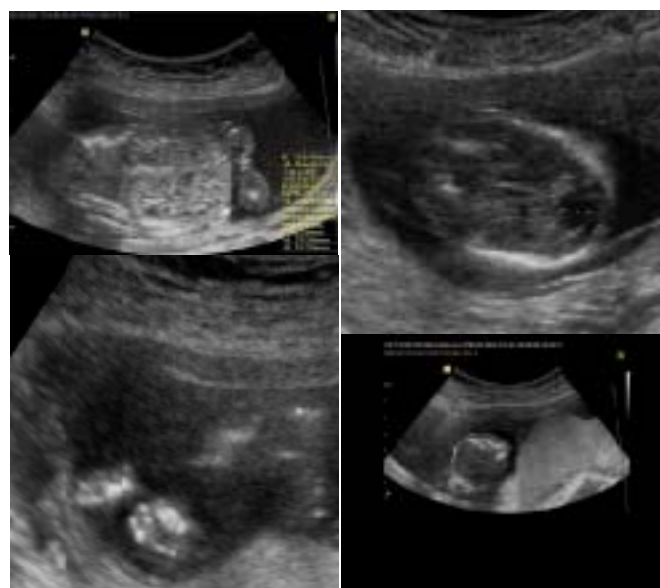

Figure 1A,B,C,D: Bilateral polycystic kidneys (A), ventriculomegaly (B), polydactyly (C), encephalocele (D)

¹ Department of Gynecology and Obstetrics Adnan Menderes University School of Medicine, Aydın

Address of Correspondence: Sümeýra Nergiz
Department of Gynecology and
Obstetrics Adnan Menderes University
School of Medicine Aydın, Turkey
sumeyranergiz80@gmail.com

Submitted for Publication: 04. 10. 2013

Accepted for Publication: 20. 11. 2013

Postmortem external examination revealed a male fetus with a weight of 118 g. Head circumference was 12 cm, abdominal circumference was 14 cm. The fetus had encephalocele and polydactyly in the both hands and feet (Figure 2). On cross-section, the cut surfaces of kidneys were both cystic in appearance like a sponge kidney. Bladder was not observed in fetus. Also fetal lungs were observed as consisting of two lobes.

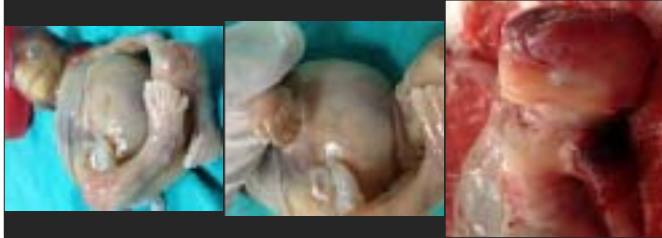


Figure 2: Postmortem findings (polydactyly and encephalocele) in MGS

Discussion

MGS is characterized by cystic kidneys, occipital encephalocele and postaxial polydactyly. Two of the three major anomalies are sufficient for the definitive diagnosis. Cystic renal dysplasia, occipital encephalocele, and postaxial polydactyly were found in 100%, 90%, and 83.3% of the fetuses, respectively.¹⁴ It was reported that 57% of the cases had three cardinal findings, but 16% had only polycystic kidney and polydactyly.¹⁵ In present case, encephalocele, postaxial polydactyly and bilateral cystic renal dysplasia were observed. When considering the differential diagnosis, mild forms of MGS may be confused with severe forms of Smith-Lemli-Opitz syndrome (microcephaly, mental retardation, cardia-pulmonary-renal malformations, and polydactyly), Bardet-Biedl syndrome (BBS; vision loss, mental retardation, renal disease, polydactyly and obesity),¹⁶ Joubert syndrome (JS; vermis hypoplasia/dysplasia, facial abnormalities, cystic renal disease, polydactyly and cleft palate), Trisomy 18 (choroid plexus cysts, congenital heart and kidney disease, clenched hands and rocker-bottom feet)¹⁷ and trisomy 13 (holoprosencephaly, cleft lip/palate, congenital heart disease and polydactyly).¹¹

MGS is a lethal syndrome, generally resulting in utero or neonatal death within a few hours of life; thus, earlier prenatal diagnosis is very important. The condition can be diagnosed sonographically in the first and second trimester.¹⁸ Earlier diagnosed cases were reported at 12+2 weeks' gestation by transabdominal ultrasound,¹⁹ at 10 weeks by embryoscopy²⁰ and at 11 weeks of menstrual age, again by embryofetoscopy.²¹ Of course these are invasive techniques for diagnosis. In present case, prenatal diagnosis by a detailed ultrasonography was performed.

MGS is an autosomal recessive disorder. Once diagnosed

in reproductive couples, their chances of subsequently giving birth to or of being diagnosed as carrying a child with MGS are 1 in 4 (25% chance) for each pregnancy. When MGS is suspected, a karyotype study should be obtained to exclude chromosomal disorder (trisomy 13).¹¹ Because the patient denied, karyotyping could not be performed in this case. If the diagnosis can be made before viability, termination can be offered as in present case. But important issue about this recurring fetal malformation is prenatal genetic counseling of couples. Many researches have been continuing but genetic mapping of the syndrome is still incomplete and several loci (MKS1, MKS3, MKS6, MKS4 (CEP290))²² are most frequent responsible genes) have been proposed, which may, in part, explain the observed phenotypic variability.^{23,24} There have been many investigations about a molecular diagnostic screening by polymerase chain reaction (PCR) for especially MKS1 and MKS3 gene mutations to diagnose MGS.^{25,17} Mostly, MKS1 mutations were determined in Turkish, Arabic, Caucasian populations with MGS.²⁵

In literature, it is claimed that detection of MGS is already possible in the first trimester. Knowledge of the underlying genetic defect helps counseling the couples with recurrence of MGS and chorionic villi sampling in the first trimester of pregnancy can be offered.²¹ Of course, actually, aim of investigations is preimplantation genetic diagnosis (PGD) of MGS which seems to be most reliable option for these families having recurrent gestations with this lethal disease, in future. However, due to the heterogeneous genetic basis, nowadays prenatal ultrasonographic signs still play a key role in the clinical diagnosis of MGS. The role of genetic testing, however, might change in the near future with the development and improvement of sequencing facilities

Meckel Gruber Sendromu – Vaka Sunumu ve Literatür Derlemesi

Meckel- Gruber sendromu (MGS) ölümcül bir otozomal resesif hastalıktır. Siliyer fonksiyon bozukluğundan kaynaklandığı düşünülmektedir. Dünya üzerindeki insidansı canlı doğumların 1/13.250 - 1/140.000'i arasında değişim göstermektedir. MGS'nin klasik triadı, santral sinir sistemi malformasyonları, tetramelik postaksiyel polidaktili ve renal kistik displazi ile karaciğer, pankreas ve epididimisteki fibrokistik değişimlerdir. Burada erken gebelik haftasında tanısı konmuş bir MGS vakası bildirilmiştir.

Anahtar Kelimeler: Meckel gruber sendromu, Ultrasonografi, Prenatal tanı

References

1. Meckel JF. Beschreibung zweier, durch sehr aehnliche.

- Bildungsabweichungen entsellter Geschwister Dutsch. Arch Physiol 1822;7:99-172.
2. Gruber GB. Beitrage zur frage "gekoppelter" missbildungen (akrocephalo-syndactylie und dysencephalia splanchnocystica). Beitr Path Anat 1934;93:459-76.
 3. Kompanje EJO. Features described and illustrated in 1684 suggesting Meckel- Gruber syndrome. Pediatr Dev Pathol 2003;6:595-8.
 4. Opitz JM, Howe JJ. The Meckel syndrome (dysencephalia splanchnocystica, the Gruber syndrome). Birth Defects 1969;2:167-79.
 5. Neyberg DA, Hallesy D, Mahony BS, Hirsch JH, Luthy DA, Hickok D. Meckel-Gruber syndrome. Importance of prenatal diagnosis. J Ultrasound Med 1990;9:691-6.
 6. Balçı S, Önal B, Erçal MD, Beksaç S, Erzen C, Akban O. Meckel Gruber syndrome: a case diagnosed in utero. Turk J Pediatr 1992;34:179-85.
 7. Cincinnati P, Neri ME, Valentini A. Dandy-Walker anomaly in Meckel-Gruber syndrome. Clin Dysmorphol 2000;9:35-8.
 8. Auber B, Burfeind P, Herold S, Schoner K, Simson G, Rauskolb R, Rehder H A disease causing deletion of 29 base pairs in intron 15 in the MKS1 gene is highly associated with the campomelic variant of the Meckel-Gruber syndrome. Clin Genet 2007;72:454-9
 9. Jones KL. Smith's Recognizable Patterns of Human Malformation (5th ed). Philadelphia: WB Saunders 1997: 184-5.
 10. Su SL, Liu CM, Lee JN. Prenatal diagnosis of Meckel-Gruber syndrome case reports. Gaoxiong Yi Xue Ke Xue Za Zhi 1995;11:127-32.
 11. Borislav A, Xiaoqing L, Chen-Chih S, Brenner D. Meckel-Gruber Syndrome Pathologic Manifestations, Minimal Diagnostic Criteria, and Differential Diagnosis Arch Pathol Lab Med 2006;130:1236-8
 12. Salonen R, Norio R. The Meckel syndrome in Finland: epidemiologic and genetic aspects. Am J Med Genet 1984;18(4):691-8.
 13. Seller MJ. Meckel syndrome and the prenatal diagnosis of neural tube defects. J Med Genet 1978;15(6):462-5.
 14. Sergi C, Adam S, Kahl P, Otto HF. Study of the malformation of the ductal plate of the liver in Meckel syndrome and review of other syndromes presenting with this anomaly. Pediatr Dev Pathol 2000;3:568-83.
 15. Balçı S, Tekşen F, Dökmeci F, Cengiz B, Cömert RB, Can B, Özdamar Ş .Prenatal diagnosis of Meckel-Gruber syndrome and Dandy-Walker malformation in four consecutive affected siblings, with the fourth one being diagnosed prenatally at 22 weeks of gestation. The Turkish Journal of Pediatrics 2004;46:283-8
 16. Karmous-Benailly H, Martinovic J, Gubler MC, et al. Antenatal presentation of Bardet-Biedl syndrome may mimic Meckel syndrome. Am J Hum Genet 2005;76:493-504.
 17. Consugar M, Kubly VJ, Lager DJ, Hommerding CJ, Wong WC, Bakker E, Gattone VH, Torres VE, Breuning MH, Harris PC Molecular diagnostics of Meckel-Gruber syndrome highlights phenotypic differences between MKS1 and MKS3. Hum Genet 2007;121:591-9
 18. Van Zalen-Sprock RM, van Vugt JM, van Geijn HP. First trimester sonographic detection of neurodevelopmental abnormalities in some single-gene disorders. Prenat Diagn 1996;16:199-202.
 19. Braithwaite JM, Economides DL. First-trimester diagnosis of Meckel-Gruber syndrome by transabdominal sonography in a low risk case. Prenat Diagn 1995;15:1168-70.
 20. Dumez Y, Domergues M, Gubler MC, et al. Meckel-Guber syndrome: prenatal diagnosis at 10 mensrual weeks using embryoscopy. Prenat Diagn 1994;14:141-44.
 21. Quintero RA, Abuhamad A, Hobbins JC, Mahoney MJ. Transabdominal thin-gauge embryofetoscopy: a technique for early prenatal diagnosis and its use in the diagnosis of a case of Meckel-Gruber syndrome. Am J Obstet Gynecol 1993;168:1552-7.
 22. Scholz CH, Jonat W, Zerres K, Bruchle NO. Earliest ultrasound findings and description of splicing mutations in Meckel-Gruber syndrome Arch Gynecol Obstet 2012; 286:917-21
 23. Paavola P, Salonen R, Weissenbach J, Peltonen L. The locus for Meckel syndrome with multiple congenital anomalies maps to chromosome 17q21-q24. Nat Genet 1995;11:213-5.
 24. Frank V, Bruchle NO, Mager S, et al. Aberrant Splicing Is a Common Mutational Mechanism in MKS1, a Key Player in Meckel-Gruber Syndrome. Hum Mut 2007; 28(6):638-9.
 25. Roume J, Genin E, Cormier-Daire V, et al. A gene for Meckel syndrome maps to chromosome 11q13. Am J Hum Genet 1998;63:1095-1101.