

# Severe Hematoma of Vulva after Vulvar Varicose Vein Surgery

Kuntay KOKANALI<sup>1</sup>, Demet KOKANALI<sup>1</sup>, Emre Göksan PABUÇCU<sup>1</sup>

Karaman, Turkey

Vulvar hematomas, causing serious morbidity and rarely mortality, usually occur after delivery. Non obstetric ones are rare conditions which is often seen after blunt trauma of vulva. Management of vulvar hematoma include conservative and surgical approaches. Surgical methods are preferred for great, complicated, expanding ones especially. We present a severe vulvar hematoma happened after vulvar varicose vein surgery and discuss the conservative approach for this case.

**Keywords:** Hematoma, Vulva, Varicose vein

Gynecol Obstet Reprod Med 2014;20:169-171

## Introduction

Varicose veins are usually found on legs, but they also can be found in the vulva.<sup>1</sup> Although, they are often considered as a cosmetic problem, they can lead to complications that results in lost time from work and lost wages. Treatment options include conservative, endovenous or interventional or surgical treatments.<sup>2</sup> Because of rich vulvar vascular network, surgical procedures for vulvar varicose veins may cause some severe complications such as hematomas. Vulvar hematomas usually occur during pregnancy or after delivery. Non-obstetric ones are uncommon conditions.<sup>3,4,5,6</sup> Management of vulvar hematomas may range from a range from a conservative method to surgical drainage. Surgical procedure is preferred in more severe cases.<sup>3</sup>

We report a severe case of vulvar hematoma happened after a surgical treatment of vulvar varicose veins and present the conservative approach to this case.

## Case Report

A 32 year-old, gravida 1, parity 1 women underwent a surgical procedure for vulvar varicose veins three days ago by department of cardiovascular surgery was referred to our clinic for her severe vulvar hematoma. She had an operation on the left part of vulva. A vulvar hematoma had been occurred at that side one day after. She had underwent ice-bag therapy with parenteral antibiotics and analgesic treatment for two days.

<sup>1</sup> Department of Obstetrics and Gynecology, Karaman State Hospital, Karaman

Address of Correspondence: M. Kuntay Kokanalı  
Department of Obstetrics and  
Gynecology Karaman State Hospital,  
Karaman, Turkey  
k.kokanal@yahoo.com.tr

Submitted for Publication: 21. 10. 2013

Accepted for Publication: 05. 12 2013

She was unable to sit down with complaints of severe perineal pain and perineal swelling. There was no past history of any medical problems in the patient. Her previous delivery was by a cesarean section. Examination of the patient revealed normal blood pressure, pulse rate and body temperature. Her abdomen examination revealed no abnormality. Genital examination revealed a swelling 5x12 cm on the left vulva, extremely tender to palpation with a bluish skin hue. Medial part of lesion was ulcerative and infected. There was also a painless, subcutaneous, superficial bleeding space with dimensions of 5x12 cm near to vulvar hematoma in the medial part of left leg. The urinary catheter had been placed. Penetrative vaginal examination could not be performed (Figure 1). In her laboratory, her blood haemoglobin was 12.2 g/dl, hematocrite was 36.6% (before the surgery, they were 12.3 and 37.2 respectively). Her bleeding and clotting time and biochemical parameters were normal. We didn't observe any pathological findings in her abdominal and pelvic ultrasonography.

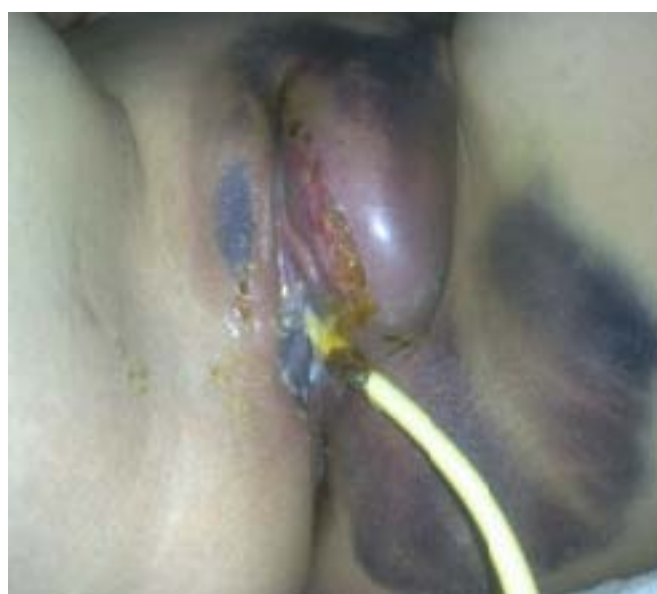

Figure 1: Vulvar hematoma at admission

We informed patient that there could be two treatment options: conservative and surgical. She preferred conservative one since she had been so disappointed and angry about her previous surgery. The culture sample from the infected part of lesion couldn't be performed. We started parenteral antibiotic (ceftriaxone 1g, twice-daily) and antiinflammatory-analgesic therapy. The antibacterial (mupirocin 2%) ointment also applied used 3-times-daily to the infected skin. Icebag compression and gently massage with heparinoid gel were applied three times a day at least for five minutes.

At the end of third day her complaints were less. The size of hematoma, blood haemoglobin and hematocrit levels were

same, which pointed out that the hematoma was restricted. Infected skin surface of vulvar hematoma was healed (Figure 2). Parenteral treatment was stopped and oral antibiotic –analgesic treatment was started. After a week of medical treatment, the patient began to sit down without any tenderness and the size of hematoma was decreased (Figure 3). She was discharged from hospital on the fourteenth day. The hematoma was smaller and the skin covered the hematoma become normal (Figure 4). Ambulatory monitoring was continued for ten-day intervals. During her outpatient follow-up period she didn't have any particular problem. About a month later she was completely healed (Figure 5). And three months after treatment she was pregnant again.

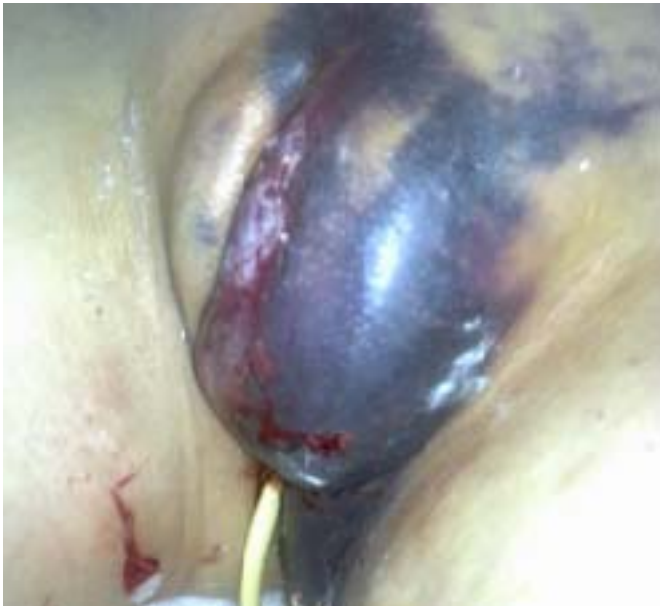

Figure 2: Vulvar hematoma 3 days after admission

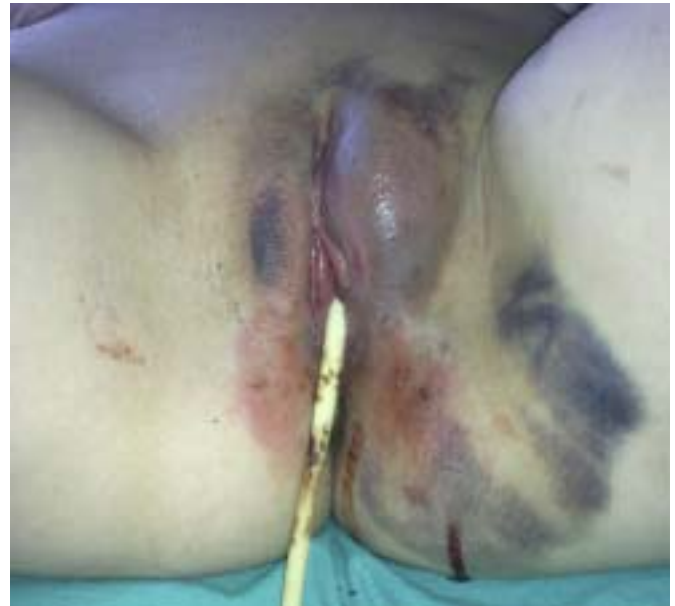

Figure 3: Vulvar hematoma 1 week after admission




Figure 4: Vulvar hematoma 2 weeks after admission



Figure 5: Vulvar hematoma 1 month after admission

## Discussion

Vulvar hematomas that constitute 0.8% of all gynaecological admissions, in tertiary and referral hospitals, generally appear after delivery. However, non-obstetric ones, often occurred after blunt traumas of vulva are relatively rare conditions. Although not common, vulvar hematomas may cause significant morbidity and rarely mortality, since the subcutaneous tissue of vulva is loose and can accumulate a large amount of blood before obvious signs and symptoms of a hematoma become apparent.<sup>7,8</sup>

The treatment options of vulvar hematomas include conservative, selective angiographic embolization of arteries and surgical drainage. Management of the vast majority of vulvar hematomas is conservative. Most resolve spontaneously as just simple precautions are taken, like tight vulvar packing. On the other hand, serial examinations must be performed to distinguish uncomplicated hematomas from those requiring surgery.<sup>8</sup> If the conservative methods are insufficient, surgical approach can be performed. Incision and drainage is advised in more severe cases to reduce infective complications and hospitalization. Benrubi et al, found that patients managed conservatively for vulvar hematomas had more subsequent operative intervention and more complications requiring antibiotics, transfusion, and more days of hospitalization than patients managed operatively. It was also found that an increased risk of complications and increased hospitalization was found with patients with hematomas managed conservatively when the product of the longitudinal diameter and the transverse diameter was 15 or greater.<sup>5</sup> In the absence of acute haematoma expansion, conservative management was often successful.<sup>9</sup> In our case, hematoma expansion was restricted, despite the product of longitudinal and transverse diameter of hematoma was great, that allowed us to treat hematoma conservatively.

If the bleeding or expansion of vulvar hematoma continue, simple incision and drainage, selective angiographic embolization of the pudendal and inferior gluteal arteries can be performed as second line treatment methods with minimal complications.<sup>10</sup>

Vulvar hematomas may cause serious morbidity and rarely mortality. The most important thing is to be careful against the process of vulvar hematomas and to diagnose and treat it earlier. In treatment, conservative and surgical methods can be applied. In the case of acute hematoma expansion and bleeding or insufficiency of conservative method, surgical approach must be performed. If the hemodynamics status of patient is stabil, hematoma is restricted and the patient is eager, the conservative treatment can be choosen.

## Vulvar Variköz Ven Cerrahisi Sonrası Vulvanın Ciddi Hematomu

Ciddi morbiditeye ve nadir olarak da mortaliteye sebep olan vulvar hematomlar çoğunlukla doğumdan sonra oluşur. Gebelik dışı olanlar nadirdir ve genellikle vulvanın künt travmaları sonrasında meydana gelirler. Tedavi yöntemleri konservatif ve cerrahi yaklaşımlardır. Cerrahi yöntemler özellikle geniş, komplike ve büyümekte olanlar için tercih edilir. Biz olgumuzda, vulvar varis cerrahisi sonrasında gelişen büyük bir vulvar hematoma olgusuna konservatif yaklaşımı tartıştık.

**Anahtar Kelimeler:** Hematom, Vulva, Variköz ven

## References

1. London NJM, Nash R. Varicose veins. *BMJ* 2000;320:1391-4.
2. Bartholomew JR, King T, Sahgal A. Varicose veins: Newer, better treatment available. *Cleveland Clinic Journal of Medicine* 2005;72:312-28.
3. Virgili A, Bianchi A, Mollica G, Corazza M. Serious hematoma of vulva from a bicycle accident. A case report. *J Reprod Med* 2000;45:662-4.
4. Propst AM, Thorp Jr JM. Traumatic vulvar hematomas: conservative versus surgical management. *South Med J* 1998;91:144-6.
5. Benrubi G, Neuman C, Nuss RC, Thompson RJ. Vulvar and vaginal hematomas: a retrospective study of conservative versus operative management. *South Med J* 1987;80:991-4.
6. Mathelier AC. Vulvar hematoma secondary to a human bite. A case report. *J Reprod Med* 1987;32:618-9
7. Sau AK, Dhar KK, Dhall GI. Nonobstetric lower genital tract trauma. *Aust N Z J Obstet Gynaecol* 1993;33:433-5
8. Gianini GD, Method MW, Christman JE. Traumatic vulvar hematomas. Assessing and treating nonobstetric patients. *Postgrad Med* 1991;89:115-8.
9. Propst AM, Thorp Jr JM. Traumatic vulvar hematomas: conservative versus surgical management. *South Med J* 1998;91:144-6
10. Villella J, Garry D, Levine G, Glanz S, Figueroa R, Maulik D. Postpartum angiographic embolization for vulvovaginal hematoma. A report of two cases. *J Reprod Med* 2001;46:65-7.