

Urethral Resection and Neo-Urethra in Invasive Vulvar Cancer

Hasan GUNGOR¹, Ibrahim TOPCU²

Gaziantep, Türkiye

ABSTRACT

Vulvar cancer is a significant gynecological malignancy. It often invades surrounding organs at the time of diagnosis. In cases of urethral invasion, lack of effective reconstruction may result in serious micturition disorders. We performed a urethral resection (surgical removal of part of the urethra) on a patient undergoing vulvar cancer surgery. Urethral invasion was detected during resection. We then created a distal neo-urethra (reconstructed lower urethra) using a vaginal flap (section of vaginal tissue reconstructed as the urethra). During the 1-year follow-up, we observed no complications. These included no urethral stenosis (narrowing), fistula formation (abnormal connection), atrophy (tissue wasting), dysuria (painful urination), or urinary disorders. When urethral invasion is found in vulvar cancer, a multidisciplinary approach is needed. Distal urethral resection and neo-urethral reconstruction are linked to good recovery and few complications.

Keywords: Flap; Neo-urethra; Vulvar cancer

Gynecol Obstet Reprod Med 2026;32(1):000-000

Introduction

Vulvar cancer is the fourth most common gynecological cancer. It represents 5% of female genital tract malignancies (1). Patients usually present with locally advanced disease. The tumor invades neighboring organs such as the vagina, anus, and urethra (2). Radical surgery aims for tumor-free margins. This reduces the need for adjuvant radiotherapy and lowers the risk of recurrence. Depending on the type and extent of urethral involvement, urethral resection is preferred to radiation (3).

Invasive vulvar surgery requires a multidisciplinary approach. There is a high risk of postoperative morbidity due to wound healing problems (4). Complications after urethral resection can cause lower urinary tract dysfunction (5). There is no consensus on whether to create a neo-urethra or the best technique. Some studies describe creating a neo-urethra with

a vaginal flap, intercalated flap, or interrupted scar in women after radical vulvar cancer surgery (6).

Few techniques and little evidence guide distal urethral neo-urethra reconstruction after radical vulva surgery for urethral invasion. Our aim is to use a vaginal flap to reconstruct a neo-urethra after distal urethrectomy. We use a multidisciplinary approach and report our oncological and urinary outcomes.

Case Report

An MRI was performed on the patient admitted to gynecology for a hard vulvar mass. MRI revealed a 42 × 19 mm diffusion-restricting lesion with peripheral contrast enhancement in the labium majus, reported as squamous cell carcinoma (Figure 1). The patient underwent tumor resection. A

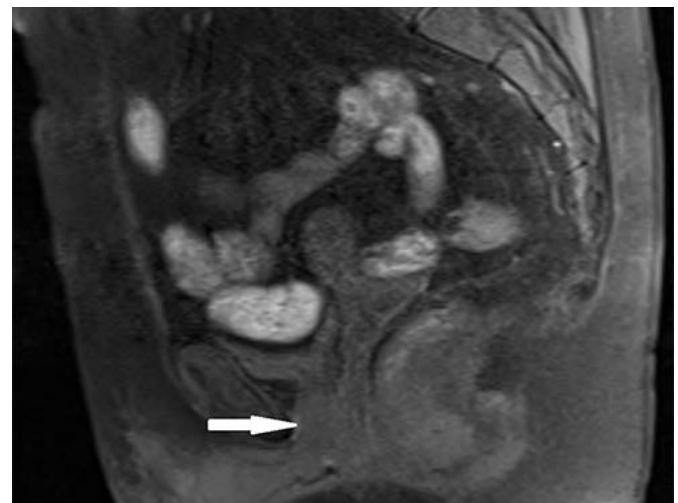


Figure 1: MRI findings in vulvar cancer with distal urethral involvement: Sagittal section of the MRI image, highlighting distal urethral involvement (white arrow)

¹ Gaziantep City Hospital Department of Urology Gaziantep, Türkiye

² Inonu University Faculty of Medicine Department of Urology Malatya, Türkiye

Address of Correspondence: Hasan Gungor
Gaziantep City Hospital Department of
Urology 27470 Gaziantep, Türkiye
dr.hasangungor@gmail.com

Submitted for Publication: 21.05.2025 Revised for Publication: 08.08.2025
Accepted for Publication: 20.04.2026 Online Published: 21.04.2026

ORCID IDs of the authors: HG: 0000-0002-6526-0255
IT: 0000-0003-4059-0597

| QR Code | Access this article online |
|---------|---|
| | www.gorm.com.tr • https://mndijital.medicalnetwork.com.tr gorm@medicalnetwork.com.tr |
| | DOI:10.21613/GORM.2025.1609 |

How to cite this article: Gungor H. and Topcu I. Urethral Resection and Neo-Urethra in Invasive Vulvar Cancer. *Gynecol Obstet Reprod Med*. 2025; (Articles in Press)



Copyright© 2026. Gungor et al. This article is distributed under a Creative Commons Attribution 4.0 International License.

frozen section study was done because the tumor was close to the urethra. Distal urethral resection was performed when the surgical margin was suspicious (Figure 2a). We then created a neo-urethra using a vaginal flap (Figure 2b). We made a circular opening as the new urethral outlet (Figure 2c).

The Foley catheter (a tube to drain urine) was removed during the first postoperative week. We monitored urine output and observed no complications. Pathology revealed squamous cell carcinoma (a type of cancer) with negative surgical margins (no tumor at specimen edge). During the 1-year follow-up, the patient had no micturition disorders (problems urinating).

Written informed consent was obtained after the patient understood the procedure and risks. Consent was given for the publication of this case report and images. All efforts were made to ensure anonymity, and no identifying information is included.

Discussion

In gynecological oncology, vulvar cancer most often affects the urethra. Surgical treatment may require radical and

reconstructive distal urethral and neo-urethral surgery (7). Urethral reconstruction is needed to preserve function. This procedure can be challenging due to patient age, vulvar and vaginal atrophy, or comorbidities (8). Later treatments, such as radiotherapy or chemotherapy, can also worsen wound healing. Reconstruction should be simple under these conditions to help with healing.

Directly suturing the urethral stump to preserved vulvar or flap skin can lead to urethral distortion, stricture, and traction injury due to potential wound contracture. This may cause micturition disturbances. For primary closure, contracture-resistant tissue should be placed between the urethra and the skin. Vaginal flaps or vesical or buccal mucosa grafts are used for urethral reconstruction in urethral loss and stenosis (9).

Three vaginal mucosa flap types exist. The first shapes the flap into a 'U' (9). The second adds two lateral incisions to create an inverted 'Y' (10). The third uses an 'X'-shaped incision along the midline for a circular neo-urethral outlet (3). We used the 'U'-shaped method in our case. The circular flap opening helps preserve distal tissue and allows for a tension-free neo-urethra (Figure 3).

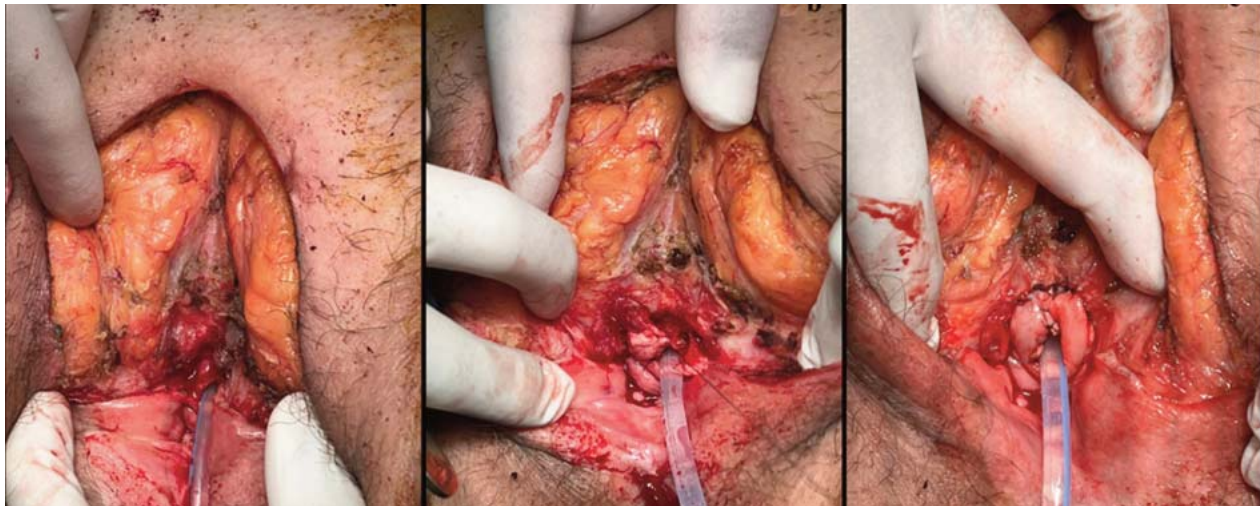


Figure 2: Surgical steps in vulvar cancer with urethral involvement, **a:** Distal urethral resection, **b:** Urethroplasty with the assistance of a vaginal flap, **c:** Neo-urethral meatus with circular opening

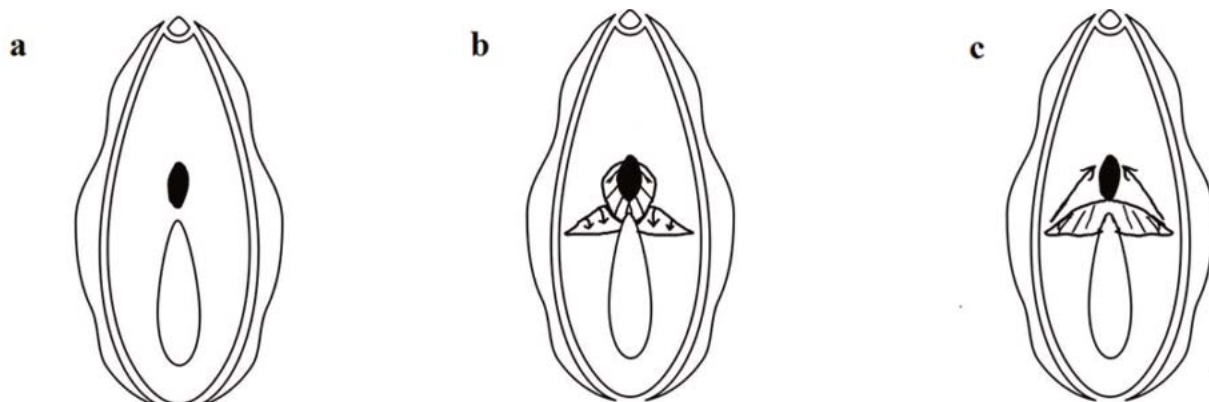


Figure 3a: Urethra mobilized from the surrounding tissues after distal urethral resection. **b:** Butterfly-shaped flap dissected from the vagina. **c:** The harvested flap anastomosed in the form of a neo-urethra

Conclusion

Vulvar cancer surgery requires a multidisciplinary approach because it is invasive and complex. Partial urethrectomy as part of radical surgery for vulvar cancer seems to increase the chances of negative surgical margins. The proposed technique for neo-urethra reconstruction resulted in good recovery and few complications, including separation, stenosis, deviation, or dribbling. However, larger, controlled, possibly randomized prospective studies are needed to confirm our results and the potential advantages of this technique.

Declarations

Ethics approval and consent to participate: This study was conducted in accordance with the principles of the Declaration of Helsinki. Written informed consent was obtained after the patient understood the procedure and risks. Consent was given for the publication of this case report and images. All efforts were made to ensure anonymity, and no identifying information is included.

Availability of data and materials: The data supporting this study are available from the corresponding author upon reasonable request.

Competing interests: The authors declare that they have no competing interests.

Funding: This study did not receive funding from any agency.

Authors' contributions: This study was conducted and written following the CRediT (Contributor Roles Taxonomy) guidelines. HG: Conceptualization, formal analysis, investigation, methodology, project administration, resources, supervision, validation, visualization, writing-original draft, writing-review and editing. IT: Data curation, investigation, methodology, writing, review, and editing. Both authors read and approved the final manuscript.

Acknowledgment: We are thankful for the valuable support of our colleagues and team members who contributed to this work.

References

- Alkatout I, Schubert M, Garbrecht N, Weigel MT, Jonat W, Mundhenke C, et al. Vulvar cancer: epidemiology, clinical presentation, and management options. *Int J Womens Health*. 2015;7:305-13. Doi: 10.2147/IJWH.S68979. PMID: 25848321, PMCID: PMC4374790.
- Woelber L, Trillsch F, Kock L, Grimm D, Petersen C, Choschzick M, et al. Management of patients with vulvar cancer: a perspective review according to tumour stage. *Ther Adv Med Oncol*. 2013;5(3):183-92. Doi: 10.1177/1758834012471699. PMID: 23634196, PMCID: PMC3630479.
- Franchi M, Uccella S, Zorzato PC, Dalle Carbonare A, Garzon S, Laganà AS, et al. Vaginal flap for urethral neomeatus reconstruction after radical surgery for vulvar cancer: a retrospective cohort analysis. *Int J Gynecol Cancer*. 2019;29(7):1098-104. Doi: 10.1136/ijgc-2019-000420. PMID: 31320484.
- Di Donato V, Bracchi C, Cigna E, Domenici L, Musella A, Giannini A, et al. Vulvo-vaginal reconstruction after radical excision for treatment of vulvar cancer: Evaluation of feasibility and morbidity of different surgical techniques. *Surg Oncol*. 2017;26(4):511-21. Doi: 10.1016/j.suronc.2017.10.002. PMID: 29113672.
- Vitale SG, Valenti G, Biondi A, Rossetti D, Frigerio L. Recent trends in surgical and reconstructive management of vulvar cancer: review of literature. *Updates Surg*. 2015;67(4):367-71. Doi: 10.1007/s13304-015-0303-6. PMID: 26070991.
- de Lorenzi F, Loschi P, Rietjens M, Sangalli C, Manconi A, Zanagnolo V, et al. Neourethral meatus reconstruction for vulvectomies requiring resection of the distal part of the urethra. *Eur J Surg Oncol*. 2015;41(12):1664-70. Doi: 10.1016/j.ejso.2015.07.017. PMID: 26365756.
- Gentileschi S, Servillo M, Garganese G, Fragomeni S, De Bonis F, Scambia G, et al. Surgical therapy of vulvar cancer: how to choose the correct reconstruction? *J Gynecol Oncol*. 2016;27(6):e60. Doi: 10.3802/jgo.2016.27.e60. PMID: 27550406, PMCID: PMC5078823.
- Matthews N, Wong V, Brooks J, Kroumpouzou G. Genital diseases in the mature woman. *Clin Dermatol*. 2018;36(2):208-21. Doi: 10.1016/j.clindermatol.2017.10.012. PMID: 29566925.
- Faiena I, Koprowski C, Tunuguntla H. Female urethral reconstruction. *J Urol*. 2016;195(3):557-67. Doi: 10.1016/j.juro.2015.07.124. PMID: 26478448.
- Montorsi F, Salonia A, Centemero A, Guazzoni G, Nava L, Da Pozzo LF, et al. Vestibular flap urethroplasty for strictures of the female urethra. Impact on symptoms and flow patterns. *Urol Int*. 2002;69(1):12-6. Doi: 10.1159/000064353. PMID: 12119432.