

# Harlequin Ichthyosis: Case Series

Huriye EZVECI<sup>1</sup>, Sukran DOGRU<sup>1</sup>, Fatih AKKUS<sup>1</sup>, Kazım GEZGINC<sup>1</sup>

Konya, Türkiye

## ABSTRACT

**OBJECTIVE:** Harlequin ichthyosis (HI) is an autosomal-recessive inherited disorder. The incidence is extremely rare and is reported to range from 1/300 000 to 1/1 000 000. Some risk factors include preterm births and consanguinity. Prenatal DNA testing for the ABCA12 mutation aids in diagnosis. Although ultrasonography helps the diagnosis, the diagnostic value of a single ultrasound is low. It is fatal for the affected newborn after the first few days after birth, but few long-term survivals have been recorded. The hallmark of with disease is severely keratinized skin. This study aims to evaluate the prenatal and post-natal outcomes of cases with HI.

**STUDY DESIGN:** The study includes instances of HI that were diagnosed at the clinic throughout 2018–2023. The week of diagnosis, ultrasonographic findings, week of birth, and findings at the time of delivery for all patients were acquired via electronic reports and archival data. Data regarding the condition of viable fetuses was acquired using telephonic means.

**RESULTS:** The study included a total of five patients. There were prenatal ultrasonography findings in three cases. There were no prenatal ultrasound findings in the remaining two patients. Cordocentesis was applied to a single case using prenatal ultrasound diagnosis, and a normal genetic result was obtained. The remaining two cases refused to opt for the option of prenatal invasive testing. The termination option was not accepted in three cases with an intrauterine diagnosis. Prenatal ultrasonography revealed features showing skin thickening, ectropion, eclabion, oligohydramnios, and fetal growth restriction (FGR). Histological examination results of fetal skin biopsies in three cases showed consistent findings of epidermolytic HI, thus confirming the diagnosis of HI. The histological diagnosis of the remaining two patients was inconclusive. All cases are alive.

**CONCLUSION:** It is advisable to conduct a methodical evaluation based on the clinical manifestations of the condition during the third trimester of gestation to diagnose HI, particularly in instances where there is no familial predisposition.

**Keywords:** ABCA12 Mutation, Harlequin ichthyosis, Ultrasonography

*Gynecol Obstet Reprod Med* 2024;30(1):19-24

<sup>1</sup> Necmettin Erbakan University Meram Faculty of Medicine, Division of Maternal and Fetal Medicine, Konya, Türkiye


**Address of Correspondence:** Huriye Ezveci  
Necmettin Erbakan University Meram  
Faculty of Medicine Division of Maternal  
and Fetal Medicine 42080 Konya, Türkiye  
huriyezveci00@gmail.com

Submitted for Publication: 08.12.2023 Revised for Publication: 08.01.2024  
Accepted for Publication: 25.01.2024 Online Published: 26.01.2024

CID IDs of the authors: HE: 0000-0002-7626-5799  
SD: 0000-0002-3383-2837 FA: 0000-0001-7037-9165  
KG: 0000-0002-3441-4960

QR Code	Access this article online
	Website: www.gorm.com.tr e-mail: info@gorm.com.tr
	DOI:10.21613/GORM.2023.1456

**How to cite this article:** Ezveci H, Dogru S, Akkus F, Gezginc K. Harlequin Ichthyosis: Case series. *Gynecol Obstet Reprod Med*. 2024;30(1):19-24

 Copyright© 2024. Ezveci et al. This article is distributed under a Creative Commons Attribution 4.0 International License.

## Introduction

Harlequin ichthyosis (HI) is classified as an uncommon genodermatological condition, characterized by an autosomal-recessive mode of inheritance. The occurrence of this phenomenon is exceptionally uncommon and has been documented to range from 1 in 300,000 to 1 in 1,000,000 (1). This particular condition is the most severe manifestation of congenital ichthyosis, which is closely linked to a mutation in the ABCA12 gene. The pathophysiology of this condition involves the development of significant disruptions in the skin's barrier function due to the disturbance of intercellular lipid deposition inside the outermost layer of the epidermis, known as the stratum corneum (2). Infants diagnosed with HI exhibit the presence of thickened plates of scale, which are distinctly demarcated by deep, erythematous fissures at birth. The integumentary system exhibits tautness due to the outward turning of the eyelids (ectropion) and lips (eclabion), accompanied by the flattening of the ears and nose, hence giving rise to a visage reminiscent of a frog. The swelling of the extremities is a result

of the restriction caused by the significant thickness of the skin (3). The fingertips have a tapering shape, accompanied by a reduction in the hyperconvexity of the nail distal digital pulp.

The utilization of prenatal diagnosis holds significance in ensuring the proper management of perinatal and postnatal care and in adequately preparing parents for future pregnancies. Prenatal diagnosis relies on the utilization of ultrasonic imaging, analysis of amniotic fluid, and molecular identification of umbilical cord blood. Nevertheless, the prenatal diagnosis of the clinical phenotype is complicated by the timing and characteristics of its emergence, particularly in cases when there is no family history (1). The clinical manifestation of the neonate in question has a deadly outcome beyond the initial days following delivery; nonetheless, there have been documented instances of long-term survival. The lethal aspect of this pathology is not the rule. Many published cases have long-term survival and a very acceptable appearance. This highlights the phenotypic variability of this condition. The primary causes of neonatal mortality are fluid loss or skin infections, electrolyte imbalances, heat loss, respiratory failure, and a lack of effective interventions (4,5).

The objective of this series was to assess the prenatal and postnatal outcomes of individuals diagnosed with HI.

## Material and Method

The study includes instances of HI that were diagnosed at the clinic of Necmettin Erbakan University Meram Medical Faculty Hospital throughout 2018-2023. Our study was conducted in accordance with applicable national rules, institutional policies, and the Declaration of Helsinki. Approval for the study was obtained from the NEU ethics committee under the decree numbered 2023/4369 (ID no: 14400). The ultrasonographical and clinical data of the patient were obtained based on the electronic medical database of the university hospital. The week of diagnosis, ultrasonographic findings, week of birth, and findings at the time of delivery for all patients were evaluated. The GE Voluson™ E8 color ultrasound diagnostic instrument with the probe frequency set from 2.5-5.0 MHz was used in the present study. After explaining to the parents all possible postnatal conditions of their fetus, the risk of intrauterine loss, and the extremity and facial anomalies seen in prenatal ultrasonography (USG), the termination op-

tion is recommended by the decision of the committee consisting of two perinatologists and one obstetrician. The status of living fetuses was obtained by contacting their families by phone. Patients without prenatal ultrasound records, cases whose postpartum diagnosis could not be confirmed, and patients who could not be reached by phone were excluded. Informed consent was obtained from the parents of all cases included in the study before the study.

## Results

The study encompassed a total of five patients. The median age of the mothers was 29 years, with a range of 22 to 33 years. The typical number of pregnancies was 2.6, ranging from 1 to 4. Three out of five instances did not have a family history. Toxoplasma, Cytomegalovirus (CMV), and Rubella IGMs in all cases were negative. Fetal facial, extremity, and skin anomalies were detected during the 25th gestational week in Case 1. In Case 2, skin and extremity anomalies were observed during the 30th gestational week. Furthermore, fetal facial, extremity, and skin anomalies were identified using ultrasound conducted during the 31st gestational week in Case 5. No prenatal USG findings were observed in the remaining two patients. A single case using prenatal ultrasound diagnostic underwent cordocentesis, yielding a normal genetic outcome. The remaining two cases declined to pursue the option of prenatal invasive testing. The termination option was not accepted in three cases with intrauterine diagnosis. The median gestational age at birth was 35 weeks (with a range of 31 to 38 weeks). Three instances were delivered via cesarean section (All three cases underwent cesarean section because they had a history of cesarean section and were in active labor), whereas two cases were delivered vaginally. As evidenced by the findings of our study, a majority of the infants exhibited premature birth. The birth weight median was recorded as 2686 grams, with a range of 1800 to 3450 grams, as seen in Table I.

In the first case, prenatal USG conducted at week 25 revealed the presence of skin thickening, ectropion, eclabion, oligohydramnios, and characteristics indicative of fetal growth restriction (FGR). During the 30th week of gestation, USG revealed the presence of skin thickening, ectropion, and eclabion in Case 2. In the fifth example, the ultrasonographic observations at 31 weeks of gestation revealed several characteristic features, including skin thickening, ectropion, a short-

**Table I:** Patient Characteristics

	Diagnose	Delivery week	Route of delivery	Gender	Family history	Histopathological diagnosis	Postnatal survival
Case 1	Prenatal	35w6d	Cesarean section	Female	No	No	5 years old
Case 2	Prenatal	38w0d	Vaginal birth	Male	Yes	Yes	4 years old
Case 3	Postnatal	35w	Vaginal birth	Male	Yes	Yes	1 year old
Case 4	Postnatal	35w4d	Cesarean section	Male	No	Yes	1 year old
Case 5	Prenatal	31w5d	Cesarean section	Male	No	No	2 months old

ened nasal bone, a flattened nose, absence of a normal mouth shape (eclabion), swelling of the fingers and toes, as well as anomalies in the limbs. Following the delivery process, the entirety of the neonate's physique was enveloped in substantial layers of dermal scales, distinctly demarcated by vivid crimson fissures. In the cases denoted as 1, 2, and 5, a distinct outward rotation of the lips, referred to as eclabion, was observed, leading to the development of a configuration resembling the letter "O" in the oral region (Figure 1a). In the fifth occurrence, the newborn had a nasal bridge with diminished prominence, resulting in a nasal look that appeared flattened (refer to Figures 1b and 2a). Nevertheless, it is important to highlight that the external ears remained constantly visible despite variations in cranial anatomy. The swelling was ob-

served in the fingertips, accompanied by a significant increase in the curvature of the distal digital pulp, resulting in the disappearance of the nail (Figures 1c and 2b).

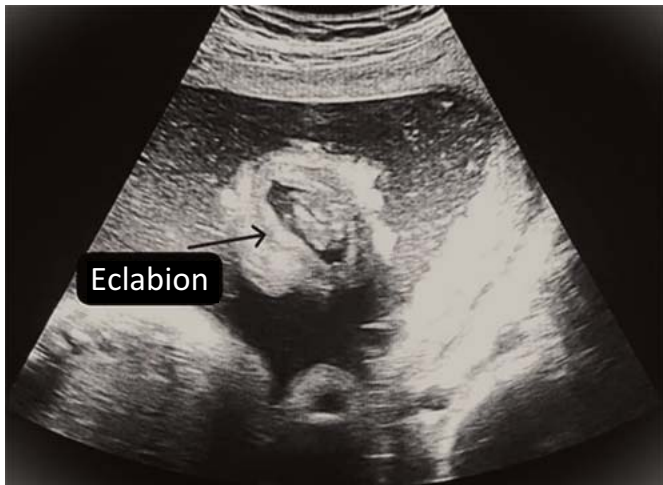

Figure 1a: 2D USG image, eclabion

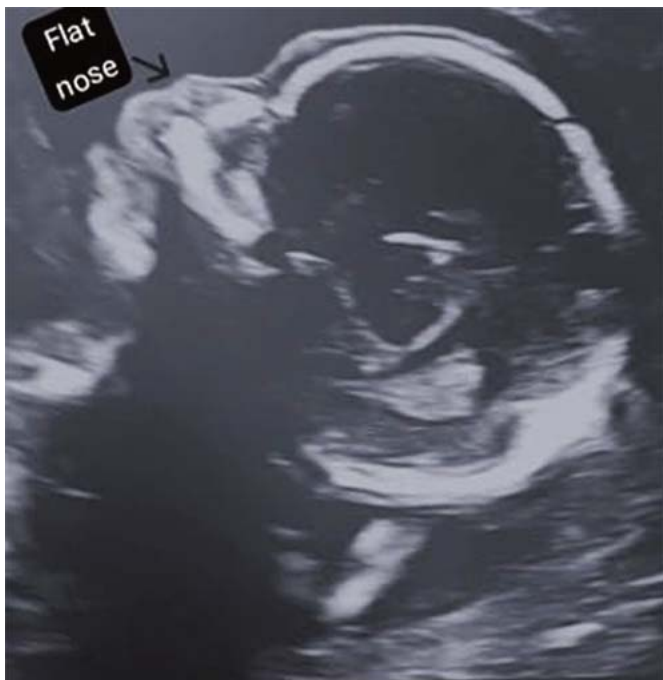

Figure 1b: 2D USG image, flat nose

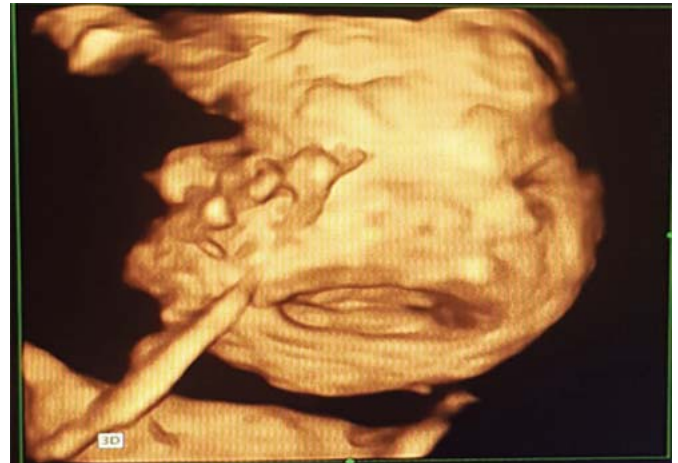

Figure 2a: 3D USG image, fetal face

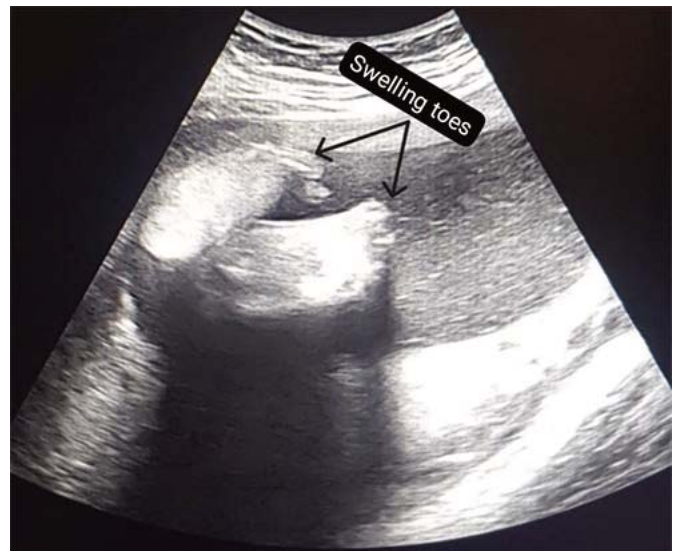

Figure 1c: 2D USG image, swelling toes

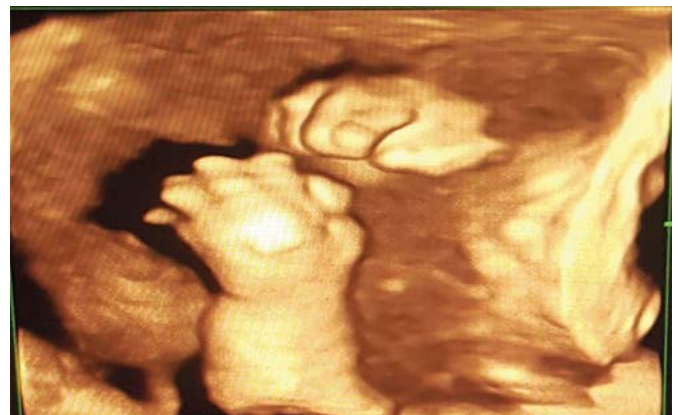
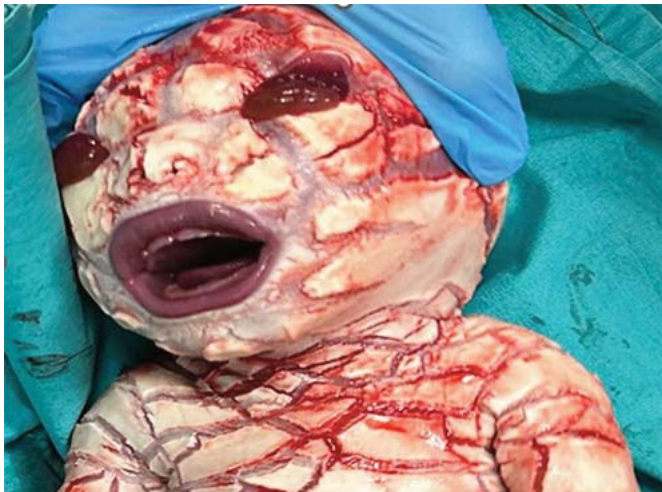
Figure 2b: 3D USG image, swelling of the fingers

The epidermis of all newborns had erythrodermic edema, characterized by the presence of greasy, thick scales resembling vernix caseosa (Figure 3). The histological examination results of fetal skin biopsies for cases 2, 3, and 4 exhibited consistent findings indicative of epidermolytic HI, thereby confirming the diagnosis of HI. The histological diagnosis for the remaining two patients was inconclusive. Case 1 was discharged after being followed in NICU for 55 days, cases 2 and 3 for 40 days, case 4 for 70 days, and case 5 for 90 days in NICU. Although all cases are alive, they are followed by a multidisciplinary team consisting of dermatology, ophthalmology, and pediatric specialists, according to telephone communication with the families.



**Figure 3:** Postpartum image

## Discussion

The topic of discussion revolves around HI, a very uncommon medical condition that exhibits an equal prevalence among individuals of both sexes. In the present case series, the identification of prenatal diagnosis was established in three instances, whereas in two cases, the diagnosis was determined based on postnatal observations. Histopathological diagnosis was successfully established in three postnatal cases, whereas the results for two cases remained inconclusive. Two cases exhibited a familial history. Three patients were delivered via cesarean section, whereas two cases were delivered through vaginal delivery.

Although the relevant gene has been identified, the presence of mutations results in diverse inequalities across individual cases, hence giving rise to a range of symptoms and impacting survival rates. Multiple investigations have documented that genetic variation in the ABCA12 gene, responsible for encoding a protein involved in lipid transportation inside the skin, contributes to the pathogenesis of the disease (6). The confirmation of ABCA12 mutation can be achieved through the analysis of chorionic villus or amniotic fluid samples (7). However, in cases where there is no family history, the target gene is not typically examined. While there have

been reports indicating that the inheritance of HI follows an autosomal recessive pattern, it is worth noting that in certain instances, including the examples we have observed, the specific inheritance pattern cannot be determined. In such cases, it is plausible that the disorder may be attributed to a novel dominant mutation (8). The subsequent pregnancy is associated with an approximate recurrence incidence of 25% (9). Within the scope of our study, two cases were found to have a family history. It was observed that the parents of these two were first-degree relatives. The parents of the remaining three cases did not have familial relationships because they were from different provinces and regions.

The utilization of ultrasound indicators in the early stages of pregnancy should be taken into consideration as a means of achieving timely and precise antenatal diagnosis of HI conditions. The process of skin keratinization typically commences during the gestational period of 22-24 weeks, leading to the manifestation of distinctive characteristics on ultrasound predominantly observed in the third trimester. Both cases that were detected by prenatal USG had gestational ages beyond the 24<sup>th</sup> week. The utilization of USG is crucial in identifying cases of HI that lack a familial background, as it allows for the observation of distinct features such as eclabion, ectropion, rudimentary ears, flexion contractures of the knees, and the presence of dense floating particles in the amniotic fluid. When HI is suspected on USG, CMV and Rubella seroconversion, which may cause fetal facial and extremity anomalies, should be checked (10). The condition known as HI, which manifests at birth, elicits a distressing image for both the affected individual's family and healthcare providers. Hence, the significance of prenatal diagnosis for this condition cannot be overstated. The delayed diagnosis of prenatal conditions is attributed to the manifestation of phenotypic traits occurring at a later stage. Postnatal diagnosis is commonly facilitated through the use of skin biopsies that showcase structural anomalies of lamellar granules, epidermal keratin expression, and the conduction of ABCA12 gene mutation testing (11).

Before the identification of the ABCA12 gene as a causative gene, prenatal diagnosis of HI was conducted using invasive procedures such as fetal skin biopsy (12,13). The utilization of ultrasound indicators in the early stages of pregnancy should be taken into consideration as a means of achieving timely and precise antenatal diagnosis of HI conditions. The process of skin keratinization typically commences during the gestational period of 22-24 weeks, leading to the manifestation of distinctive characteristics on ultrasound predominantly observed in the third trimester. Both cases that were detected by prenatal USG had gestational ages beyond the 24<sup>th</sup> week. The utilization of USG is crucial in identifying cases of HI that lack a familial background, as it allows for the observation of distinct features such as eclabion, ectropion, rudimentary ears, flexion contractures of the knees, and the presence of dense floating particles in the amniotic fluid. The

condition known as HI, which manifests at birth, elicits a distressing image for both the affected individual's family and healthcare providers. Hence, the significance of prenatal diagnosis for this condition cannot be overstated. The delayed diagnosis of prenatal conditions is attributed to the manifestation of phenotypic traits occurring at a later stage. Postnatal diagnosis is commonly facilitated through the use of skin biopsies that showcase structural anomalies of lamellar granules, epidermal keratin expression, and the conduction of ABCA12 gene mutation testing (11).

Before the identification of the *abca12* gene as a causal gene, prenatal diagnosis of HI was performed using invasive methods such as fetal skin biopsy accompanied by USG or fetoscopy during the 21<sup>st</sup> and 22<sup>nd</sup> weeks of pregnancy (13,14). Advances in ultrasound technology and the utilization of fetal DNA-based analysis have resulted in the replacement of the aforementioned method (15). The analysis of prenatal sonography pictures of fetuses with HI has been conducted to monitor several manifestations of the condition, such as eclabium, ectropion, contractures, and the presence of the "snowflake sign" (characterized by the observation of dense floating particles in the amniotic fluid).

As in the case reports shown, 3D/4D USG confirms suspicious findings on 2D USG by producing aesthetically realistic images that are very similar to photographs, allowing parents to fully comprehend the precise characteristics of the anomaly (16-18). Unless explicitly pointed out by the operator, it is highly unlikely for parents to detect any fetal anomalies using 2D scanning. By utilizing three-dimensional and 4-dimensional ultrasound images, parents have a high probability of detecting an anomaly at the same time as the doctor or sonographer doing the scan. Nevertheless, it is important to note that 3D ultrasound technology is unable to serve as a substitute for 2D ultrasound technology. The majority of instances manifest during the latter stages of pregnancy. During this particular developmental phase, there is a decrease in the volume of amniotic fluid and the positioning of the fetus becomes more stable. The majority of fetuses are unable to undergo 3D imaging, necessitating the reliance on 2D diagnostic methods.

The presence of extensive fissures on the dermal surface compromises the skin's protective function, rendering it more susceptible to infection. The restriction of respiratory movements is attributed to the presence of inflexible thick membranes covering the chest and the entire body, resulting in an elevated risk of mortality associated with respiratory failure. Ectropion, eclabium, auricular flattening, digital deformities with autoamputation, hypo- or hyperthermia, electrolyte imbalances, as well as pulmonary and cutaneous infections have been identified as potential factors contributing to mortality within the initial days following birth (19,20). Nevertheless, as a result of advancements in newborn intensive care facilities and the use of targeted medicines, the outlook for infants

with HI conditions has experienced a notable enhancement. According to a study, a survival rate of 56% has been shown, with a range of 10 months to 25 years (21). In this particular series, all individuals were found to be living, with the eldest among them being 5 years of age.

In conclusion, the significance of intrauterine diagnosis alongside the monitoring of fetal growth and amniotic fluid during the third trimester provides valuable information to parents and the health care team, enabling them to make appropriate preparations for the impending birth of the baby.

*Research funding: None declared.*

*Author contributions: All authors have accepted responsibility for the entire content of this manuscript and approved its submission.*

*Acknowledgements: Thanks to all colleagues. Informed consent was obtained from all parents included in this study. Permission was obtained from the parents of the patients for all materials (patient's photographs, radiological images, etc.) used in the study.*

*Disclosure: Authors state no conflict of interest.*

*Ethical approval: Research with human subjects complies with all relevant national regulations and institutional policies and the principles of the Declaration of Helsinki (revised in 2013) and was approved by the NEU Ethics Committee with the decree numbered 2023/4369 (14400).*

*Authors' contributions: HE: Project development, Data management, manuscript writing. ŞD: Data management, manuscript editing. FA: Data management. KG: Protocol and project development.*

## References

1. Zhou Y, Li L, Wang L, Zhang C. Prenatal diagnosis of a rare variant of harlequin ichthyosis with literature review. *BMC Med Imaging*. 2021;21(1):56. Doi: 10.1186/s12880-021-00586-4. PMID: 33743627, PMCID: PMC7981911..
2. Jian W, Du QT, Lai ZF, Li YF, Li SQ, Xiong ZT, et al. Prenatal diagnosis of a fetus with Harlequin ichthyosis in a Chinese family. *Taiwan J Obstet Gynecol*. 2018;57(3): 452-5. Doi: 10.1016/j.tjog.2018.04.023. PMID: 29880184.
3. Hovnanian A. Harlequin ichthyosis unmasked: a defect of lipid transport. *J Clin Invest*. 2005;115(7):1708-10. Doi: 10.1172/JCI25736. PMID: 16007249, PMCID: PMC 1159155.
4. Shahada O, Kurdi A, Al Ahmadi D. Harlequin Ichthyosis: A fatal case report in Al-Medina, Saudi Arabia. *Cureus*. 2022;14(3):e23533. Doi: 10.7759/cureus.23533. PMID: 35495007, PMCID: PMC9045548.
5. Habib A, Pasha W, Raza N, Hameed A. Harlequin ichthyosis in two siblings. *J Coll Physicians Surg Pak*. 2011;21(8):503-5. PMID: 21798141.
6. Fatima S, Rafiq A, Majid Z. Harlequin ichthyosis in an in-

- fant born to a father with eczema. *J Trop Pediatr.* 2015; 61(2):143-5. Doi: 10.1093/tropej/fmu072. PMID:25539778.
7. Akiyama M, Titeux M, Sakai K, McMillan JR, Tonasso L, Calvas P, et al. DNA-based prenatal diagnosis of harlequin ichthyosis and characterization of ABCA12 mutation consequences. *J Invest Dermatol.* 2007;127(3):568-73. Doi: 10.1038/sj.jid.5700617. PMID: 17082782.
  8. Kelsell DP, Norgett EE, Unsworth H, Teh MT, Cullup T, Mein CA, et al. Mutations in ABCA12 underlie the severe congenital skin disease harlequin ichthyosis. *Am J Hum Genet.* 2005;76(5):794-803. Doi: 10.1086/429844. PMID: 15756637, PMCID: PMC1199369.
  9. Couto PA, Pastore MC, Araújo JC, Mota CM, Chirano CA, Ferreira VK, et al. Harlequin ichthyosis: case report. *Revista SPDV.* 2019;77(1):55-8. Doi: 10.29021/spdv.77.1.984.
  10. Ozel A, Canday M, Yurtkal A, Davutoglu EA, Akpak YK, et al. Seroprevalence rates of *Toxoplasma gondii*, Rubella, Cytomegalovirus among first trimester pregnant women in Istanbul. *Int J Reprod Contracept Obstet Gynecol.* 2021;10(1):22-5. Doi: 10.18203/2320-1770.ijrcog20205749.
  11. Rathore S, David LS, Beck MM, Bindra MS, Arunachal G. Harlequin Ichthyosis: Prenatal diagnosis of a rare yet severe genetic dermatosis. *J Clin Diagn Res.* 2015; 9(11): QD04-6. Doi: 10.7860/JCDR/2015/15250. 6705. PMID: 26675324, PMCID: PMC4668483.
  12. Zieger K, Weiner J, Krause K, Schwarz M, Kohn M, Stumvoll M, et al. Vaspin suppresses cytokine-induced inflammation in 3T3-L1 adipocytes via inhibition of NFκB pathway. *Mol Cell Endocrinol.* 2018;460:181-8. Doi: 10.1016/j.mce.2017.07.022. PMID: 28756250.
  13. Akiyama M, Suzumori K, Shimizu H. Prenatal diagnosis of harlequin ichthyosis by the examination of keratinized hair canals and amniotic fluid cells at 19 weeks' estimated gestational age. *Prenat Diagn.* 1999;19(2):167-71. PMID: 10215076.
  14. Blanchet-Bardon C, Dumez Y, Labbé F, Lutzner MA, Puissant A, Henrion R, Bernheim A. Prenatal diagnosis of Harlequin fetus. *Lancet.* 1983;1(8316):132. Doi: 10.1016/s0140-6736(83)91780-4. PMID: 6129450.
  15. Ahmed H, O'Toole EA. Recent advances in the genetics and management of harlequin ichthyosis. *Pediatr Dermatol.* 2014;31(5):539-46. Doi: 10.1111/pde.12383. PMID: 24920541.
  16. Basgul AY, Kavak ZN, Guducu N, Durukan B, Isci H. Prenatal diagnosis of congenital harlequin ichthyosis with 2D, 3D, and 4D ultrasonography. *Clin Exp Obstet Gynecol.* 2011;38(3):283-5. PMID: 21995167.
  17. Vohra N, Rochelson B, Smith-Levitin M. Three-dimensional sonographic findings in congenital (harlequin) ichthyosis. *J Ultrasound Med.* 2003;22(7):737-9. Doi: 10.7863/jum.2003.22.7.737. PMID: 12862276..
  18. Benoit B. Three-dimensional ultrasonography of congenital ichthyosis. *Ultrasound Obstet Gynecol.* 1999;13 (5): 380. Doi: 10.1046/j.1469-0705.1999.13050380.x. PMID: 10380314.
  19. Rajpopat S, Moss C, Mellerio J, Vahlquist A, Gånemo A, Hellstrom-Pigg M, et al. Harlequin ichthyosis: a review of clinical and molecular findings in 45 cases. *Arch Dermatol.* 2011;147(6):681-6. Doi: 10.1001/archdermatol.2011.9. PMID: 21339420.
  20. Shrestha AB, Biswas P, Shrestha S, Riyaz R, Nawaz MH, Shrestha S, Hossainy L. Harlequin ichthyosis: A case report and literature review. *Clin Case Rep.* 2022;10 (12):e6709. Doi: 10.1002/ccr3.6709. PMID: 36483862; PMCID: PMC9723482.
  21. Tahir A, Tariq SM, Haider SA, Hasan M. Ichthyosis Congenita, Harlequin Type: A fatal case report. *Cureus.* 2018;10(10):e3524. Doi: 10.7759/cureus.3524. PMID: 30648059, PMCID: PMC6318104.