

Additive Effect of Fetal Magnetic Resonance Imaging to Prenatal Ultrasonography in Fetal Congenital Anomalies

Emine KIRTIS¹, Gul ALKAN BULBUL¹, Hulya KANDEMİR¹, Cem Yasar SANHAL¹, Kamil KARAALI², Ibrahim Inanc MENDILCIOGLU¹

Antalya, Türkiye

ABSTRACT

OBJECTIVES: In this study, we aimed to assess the diagnostic accuracy of prenatal Ultrasonography (USG) and Magnetic Resonance Imaging (MRI) in fetal congenital anomalies.

STUDY DESIGN: A retrospective cross-sectional analysis was conducted on 148 patients who had previously undergone prenatal MRI between January 2013 and May 2023. A total of 185 anomalies in 148 fetuses were evaluated using USG and MRI. The prenatal diagnoses were compared with definitive diagnoses and were classified as diagnosed, partially correct, questionable, or undiagnosed. In addition, USG and MRI findings were compared in terms of their consistency and consolidation.

RESULTS: The postnatal evaluation revealed a total of 185 anomalies in 148 fetuses. USG diagnosed 94% of these anomalies, while MRI diagnosed 95.1% of them. Both USG and fetal MRI were able to diagnose 91.9% (n=170) of anomalies during the prenatal period. Fetal MRI provided an additional contribution to USG in the diagnosis of six anomalies (3.24%).

CONCLUSION: In fetuses undergoing detailed ultrasonography and specialized neurosonography by experienced professionals, additional fetal anomalies exclusively detected through MRI are now found to be lower than previously documented. However, fetal MRI is presently employed to offer supplementary information, and advice, and assist in clinical decision-making. In the future, extensive prospective studies with standardized protocols for ultrasound imaging of the fetal brain are necessary to better understand the true role of fetal MRI in cases where fetal neurosonography has already been performed.

Keywords: Fetal anomaly; Fetal magnetic resonance imaging; Fetal ultrasonography; Fetus

Gynecol Obstet Reprod Med 2024;30(1):25-32

¹ Department of Gynecology & Obstetrics School of Medicine Akdeniz University Antalya, Türkiye

² Department of Radiology School of Medicine Akdeniz University Antalya, Türkiye

Address of Correspondence: Emine KIRTIS
Akdeniz University Hospital Gynecology and Obstetrics Clinic, H Block, 1st Floor,
Dumlupinar Neighborhood, Konyaalti/
Antalya/ Türkiye
edogru07@hotmail.com
dredogru@gmail.com

Submitted for Publication: 18.09.2023 Revised for Publication: 07.01.2024

Accepted for Publication: 22.04.2024 Online Published: 24.04.2024

ORCID IDs of the authors: EK: 0000-0002-6017-8228
GAB: 0000-0002-6773-4573, HK: 0000-0001-8218-1893
CYS: 0000-0003-0007-5769, KK: 0000-0002-2716-4422
IIM: 0000-0001-5611-5518

QR Code	Access this article online
	Website: www.gorm.com.tr e-mail: info@gorm.com.tr
	DOI:10.21613/GORM.2023.1438

How to cite this article: Kirtis E, Alkan Bulbul G, Kandemir H, Sanhal CY, Karaali K, Mendilcioglu II. Additive Effect of Fetal Magnetic Resonance Imaging to Prenatal Ultrasonography in Fetal Congenital Anomalies. *Gynecol Obstet Reprod Med*. 2024;30(1):25-32



Copyright© 2024. Kirtis et al. This article is distributed under a Creative Commons Attribution 4.0 International License.

Introduction

Ultrasonography (USG) is widely recognized as the primary screening tool for fetal imaging due to its safety, cost-effectiveness, wide availability, real-time display, and well-established literature data (1-3). However, the sensitivity and specificity of USG may be reduced by factors such as fetal position, oligohydramnios, maternal obesity, and fetal ossification (1,2). In such cases and specific clinical scenarios with abnormalities detected by USG, Magnetic Resonance Imaging (MRI) may provide important diagnostic information (2).

MRI is a non-invasive diagnostic tool that does not involve ionizing radiation, and according to the Safety Committee of the MRI Society, no adverse side effects or delayed sequelae have been reported (4). One of the main advantages of MRI is its ability to provide multi-planar visualization of all organs with excellent soft tissue contrast. The main disadvantage of MRI, which is image artifact due to fetal movement, has been overcome with the development of ultra-fast arrays in the 1990s, allowing fetal imaging without the need for maternal and fetal sedation. Advanced MRI has successfully diagnosed central nervous system (CNS) abnormalities (5). Ventriculomegaly is the most common indication in CNS

imaging and suspected corpus callosum abnormalities, cerebellar anomalies, congenital infections, cortical developmental malformations, and posterior fossa anomalies are frequently investigated causes (2). Additionally, MRI can provide additional information in cases with non-CNS pathologies, such as abdominal, pelvic, and lung masses, including mass characteristics and volumetric data (6).

Within the scope of this research, we aimed to analyze the fetal MRI results of individuals in our tertiary care center and assess the contribution of MRI to USG in the evaluation of fetal abnormalities.

Materials and methods

A retrospective cross-sectional analysis was conducted to investigate the use of MRI combined with prenatal USG in a tertiary care clinic. Between January 2013 and May 2023, 188 patients requested fetal MRI after USG. Out of the 188 cases, postpartum data were unavailable for 38 cases, and 2 cases were still ongoing pregnancies, leading to the exclusion of 40 cases from the postpartum evaluation. Postnatal data from 148 cases were included in the retrospective analysis, and a total of 185 anomalies in 148 fetuses were evaluated with both USG and MRI. The study adhered to ethical standards set by the institutional and national committee responsible for human experiments and the 1975 Declaration of Helsinki, revised in 2008. The institution granted ethics committee approval on 23 August 2023 with protocol number KAEK-648.

In cases where multiple abnormalities were detected in prenatal USG, the one associated with the reason for requesting fetal MRI was classified. Fetal MRI indications were classified based on organ systems. The definitive postnatal diagnosis was conducted via physical examination, radiological imaging, surgery, autopsy, pathological examination, and clinical follow-up. Patient data were obtained by reviewing patient files, pathology reports, and postpartum files of fetuses and making phone calls with the families.

Ultrasound Imaging: Two high-resolution scanners, Voluson E8 (GE Healthcare Austria GmbH&Co OG) and Toshiba Aplio E500 (Shimoishigami, Otawara-Shi, Tochigi324-8550, Japan), were used for prenatal USG examinations. The examinations were performed by a perinatologist with more than ten years of high-risk obstetric USG experience using abdominal and vaginal probes. When necessary, the optimal position of the fetus was waited for, and the examination was repeated multiple times using transvaginal and transabdominal USG. USG examinations were done under The International Society of Ultrasound in Obstetrics and Gynecology (ISUOG) practice guidelines. The fetal cranial assessment included the examination of cranial shape, cavum septum pellucidum, falx cerebri, thalami, cerebral hemispheres, ventricles, the cerebellum, and cisterna magna. For fetal spinal evaluation, both longitudinal and axial sections

were analyzed to assess the integrity of the vertebral column at all levels. The examination encompassed the identification of vertebral anomalies, sacral agenesis, spina bifida, and the presence of meningocele or meningomyelocele. Additionally, the examination extended to verifying the integrity of the skin and identifying any additional anomalies in both the cranial and spinal regions. In fetal face examination, both orbits and bulbs, midsagittal facial profile, nasal bone, lips, and neck were evaluated for the absence of masses (e.g., cystic hygroma).

Shape and size of chest and lungs, heart activity and rhythm, heart position, four-chamber view of the heart (left chambers on the left side), aortic and pulmonary outflow tracts (relative size and relationships), left ventricular outflow tract (LVOT) view; three-vessel view or three-vessels-and-trachea-view were evaluated. Diaphragmatic integrity was evaluated for signs of diaphragmatic hernia, and the positions of the stomach, bowel (not dilated or hyperechogenic) and gallbladder were thoroughly examined. The examination also involved a meticulous view of both kidneys and the urinary bladder, along with an assessment of the cord insertion site on the fetus's abdomen. Additional axial, coronal, and sagittal planes were used to evaluate the fetal face, neck, thorax, and abdomen for any potential anomalies, ensuring a comprehensive assessment of fetal anatomy (6-8).

USG of patients referred from an external center were repeated, and current USG findings were used in data analysis. All MRI examinations were performed within the first week after fetal USG.

MRI Imaging: The fetal MRI examinations were conducted using a 1.5 Tesla and 3 Tesla MRI device, namely the 1.5 T Magnetom Avanto (Siemens, Erlangen, Germany) and Siemens Magnetom Spectra 3T MRI Machine (Siemens, Germany), respectively. The fetal MRIs were performed in the left lateral decubitus or supine position without using contrast and without the need for maternal or fetal sedation. Ultrafast T2-W sequences were primarily used for fetal MRIs, which are single-shot rapid acquisition with refocused echoes (9). Fetal cross-sectional images were taken in the coronal, axial, and sagittal planes and interpreted by a radiologist experienced in fetal MRI. The radiologist was aware of the prenatal USG data and was not blinded to the study.

Fetal Anomaly Classification and Indications for Fetal MRI: The fetal MRI was specifically requested to investigate the underlying etiology of ventriculomegaly, and to obtain additional sequences and complementary examinations in instances involving corpus callosum dysgenesis, cortical development malformations, and anomalies in the posterior fossa. In 15 out of the 16 cases where neural tube defects (NTD) were identified and the decision was made to proceed with the pregnancy, the extent of cerebellar herniation was subject to evaluation by multidisciplinary experts, including surgeons, neurosurgeons, neurologists, etc. This collaborative assess-

ment aimed to contribute to postnatal prognosis prediction, surgical planning, and comprehensive family counseling. Additionally, in one particular case, fetal MRI was specifically requested for academic study purposes.

Fetal cranial ventriculomegaly is typically defined as a cranial ventricular atrium diameter of 10 mm or greater on prenatal USG. Depending on the classification system used, fetal ventriculomegaly may be categorized as mild (10-15 mm) or severe (>15 mm), or as mild (10-12 mm), moderate (13-15 mm), or severe (>15 mm) (10, 11). In our study, we used the first definition to categorize the patients.

Corpus callosum (CC) anomalies were divided into three categories: (i) complete agenesis of the corpus callosum (CACC); (ii) partial agenesis of the corpus callosum (PACC); and (iii) dysgenetic corpus callosum (DCC). CACC was described as the inability to visualize CC in the sagittal plane of the fetal brain. PACC was defined as when the anterior portion of the CC was present, but the length of its measurement was below the 3rd percentile according to the nomogram described by Achiron et al. (2001) or partial absence of the corpus or splenium (12). DCC was defined as abnormal CC thickness.

When evaluating non-CNS anomalies, the use of MRI is much more limited and can be used as a complementary imaging method in special cases. When considering MRI indications for anomalies in other systems, it was deemed necessary to employ MRI techniques to measure residual lung volume and assess the position of the liver in cases of diaphragmatic hernia with thoracic anomalies; fetal MRI was also requested for the differential diagnosis of hyperechoic lung lesions. While the USG method exhibits high specificity and sensitivity for assessing urogenital anomalies such as renal agenesis, ectopic kidney, polycystic and multicystic kidney, and others, limitations arise in cases characterized by severe oligohydramnios observed during prenatal sonography. In response to these challenges posed by suboptimal sonic windows, MRI was employed in seven instances. In one particular case, the decision to utilize MRI was prompted by familial concern and a family request arising from a history of severe renal failure, aiming to enhance the precision of prenatal counseling.

The prenatal diagnoses were compared with definitive diagnoses and classified as diagnosed, partially correct, questionable, or undiagnosed.

In addition, the USG and MRI findings were compared in terms of inconsistency and consolidation. The data were grouped as follows:

1. Both USG and MRI are correct.
2. Both USG and MRI are incorrect.
3. MRI contributed to USG:
 - a. USG is incorrect, MRI is true.
 - b. MRI showed additional findings to USG.
 - c. MRI confirmed the suspected diagnosis of USG.
4. USG correct, MRI failed.

Statistical analysis

The USG and MRI data were analyzed to determine the consistencies and discrepancies between the two methods. The diagnostic performance of each method was compared using the sign test, with significance defined as a P-value less than 0.05.

Results

In this study, the mean gestational age at the time of USG was 24.2 ± 5.4 weeks, and fetal MRI was performed within one week at the latest, between 20-35 weeks of gestation. According to postnatal evaluation, a total of 185 anomalies were detected in 148 fetuses and 157 of these anomalies included CNS anomalies. CNS anomalies are categorized in Table I. Of these 185 anomalies, 94% were diagnosed by USG and 95.1% were diagnosed by MRI. Table II presents the accuracy of USG or fetal MRI in the diagnosis of fetal anomalies, while Table III shows the comparison of USG and fetal MRI findings with postnatal diagnosis and the agreement between them.

Both USG and fetal MRI were able to diagnose 91.9% (n=170) of anomalies during the prenatal period. The heterotopia case recognized by both USG and MRI is shown in Figure 1. In this study, when evaluating the contribution of fetal MRI to USG according to organ systems, we found that its contribution to CNS anomalies was 3.2%. However, no contribution of fetal MRI was observed in face-neck anomalies, teratomas, gastrointestinal system (GIS), and genitourinary system (GUS) anomalies. In thoracic anomalies, an additional contribution of 14.2% was noted. Fetal MRI has provided additional value to USG in the diagnosis of a total of six anomalies (3.24%). For the first one who was referred with the suspicion of the partial absence of cavum septum pellucidum (CSP) (single leaf on its lateral wall), two leaves of CSP were observed in fetal MRI, indicating a more detailed and accurate diagnosis. The second case was a periventricular leukomalacia detected via fetal MRI of one of the twins, providing valuable information for appropriate management. In the third case, in addition to hemimegalencephaly observed in fetal USG, heterotopia was observed in MRI. In the fourth case, the location of the cystic lesion on USG could not be evaluated clearly due to fetal ossification, fetal MRI reported it as an intraventricular arachnoid cyst. In addition, in a fetus with suspected vermis hypoplasia, MRI reported vermis as normal. Finally, MRI was requested with the detection of a hyperechoic thoracic mass in the fetal USG scan, MRI detected that the mass was feeding from the aorta, leading to a diagnosis of bronchopulmonary sequestration (BPS). These findings highlight the additional diagnostic capabilities of fetal MRI in certain cases where USG may have limitations, demonstrating its clinical utility in prenatal anomaly detection and management.

Table I: The distribution of subgroups of CNS abnormalities in numbers and percentages.

CNS Anomalies	N:157 (%)	Subgroup (Number of cases)
Ventricular anomalies	67 (42.7%)	Mild ventriculomegaly (52) Severe ventriculomegaly (15)
Posterior fossa anomalies	23 (14.6%)	Isolated cerebellar hypoplasia (6) Vermian hypoplasia (3) Dandy-Walker malformation (3) Blake's Poushe cyst (2) Mega cisterna magna (9)
Midline anomalies	28 (17.8%)	Complete CC agenesis (6) Partial CC agenesis (6) CC dysgenesis (4) Absent cavum septum pellucidum (12)
Cortical malformations	9 (5.7%)	Lissencephaly (2) Agria (1) Schizencephaly (3) Hemimegalencephaly(1) Heterotopia (2)
Neural tube defects	16 (10.2%)	Chiari II malformations (15) Meningocele (1)
Intracranial cyst	10 (6.4%)	Arachnoid cyst (2) Interhemispheric cyst (6) Periventricular cyst (1) Connatal cyst (1)
Intracranial calcification	1 (0.6%)	Falx serebri calcification (1)
Hemorrhagic lesions	3 (1.9%)	Germinal matrix hemorrhage (3)

CNS: Central nervous system, CC: corpus callosum, N: number of cases

Table II: USG and MRI Imaging Diagnoses

Postnatal Diagnosis	Number of Cases	Diagnosed		Questionable		Partially Correct		Undiagnosed	
		USG	MRI	USG	MRI	USG	MRI	USG	MRI
CNS anomalies	157	150	152	2	0	3	3	2	2
Genitourinary system	6	6	5	0	0	0	0	0	1
Facial-Neck anomalies	11	9	9	1	1	0	0	1	1
Thorax	7	6	7	0	0	1	0	0	0
Gastrointestinal system	2	1	1	0	0	1	1	0	0
Teratoma	2	2	2	0	0	0	0	0	0
Total	185	174 (94%)	176 (95.1%)	3 (1.6%)	1 (0.5%)	5 (2.7%)	4 (2.2%)	3 (1.6%)	4 (2.2%)

CNS: Central nervous system, USG: ultrasonography, MRI: magnetic resonance imaging. Diagnosed: Prenatal and postnatal diagnoses are the same. Questionable: prenatal suspected anomalies confirmed postnatally. Partially correct: prenatal anomaly is identified postnatally (prenatal pulmonary hyperechogenic mass postnatally diagnosed as cpam or ps). Wrongly/undiagnosed: prenatal diagnoses changed postnatally or the anomaly was not imaged postnatally

Table III: Comparison of USG & MRI and Postnatal Imaging Findings

Postnatal Diagnosis	Number of Cases	MRI&USG correct	MRI&USG failed	Additional findings*	MRI failed**
CNS anomalies	157	147 (93.6%)	2 (1.3%)	5 (3.2%)	3 (1.9%)
Genitourinary system	6	5 (83.3%)	-	-	1 (16.7%)
Facial-Neck anomalies	11	9 (81.8%)	2 (18.1%)	-	-
Thorax	7	6 (85.7%)	-	1 (14.2%)	-
Gastrointestinal system	2	1 (50%)	1 (50%)	-	-
Teratoma	2	2 (100%)	-	-	-
Total	185	170 (91.9%)	5 (2.7%)	6 (3.24%)	4 (2.1%)

CNS: Central nervous system, USG: ultrasonography, MRI: magnetic resonance imaging.

*: In this group, MRI confirmed the suspicious USG diagnosis, showed additional findings, or changed the USG diagnosis.

** : In this group, USG diagnoses were accurate or partially accurate but MRI was undiagnosed.

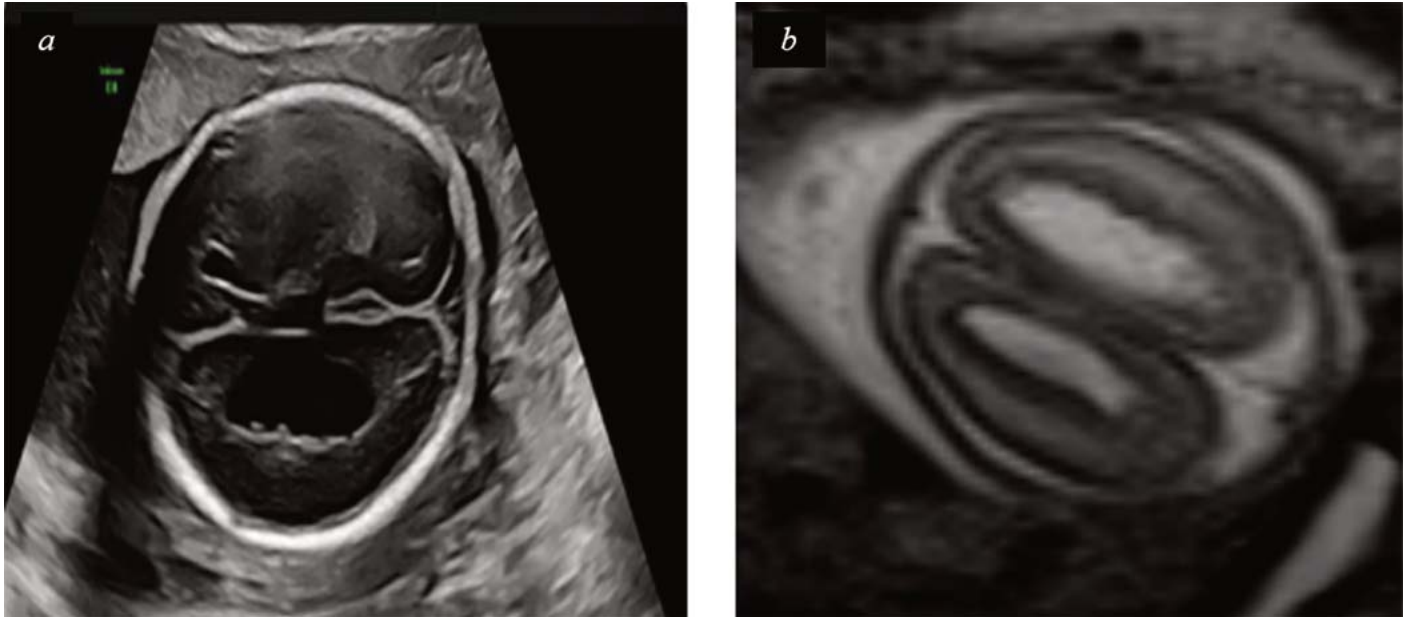


Figure 1: A fetus with heterotopia on antenatal ultrasound at 22 gestational weeks with a missense mutation of the *FLNA* gene (a) Axial image performed at 22 gestational weeks showing heterotopia (b) Brain MRI scan of the same fetus, axial section.

In four cases, fetal MRI was unsuccessful in evaluating anomalies that had been detected by prenatal USG. The first case was a 27-week-old fetus who presented with suspicion of germinal matrix bleeding on USG examination, but fetal MRI misdiagnosed the case as ventriculomegaly. In another case, fetal MRI initially interpreted cranial imaging as normal, while USG had diagnosed an interhemispheric cyst. However, the cyst was eventually observed in postnatal MRI, indicating a discrepancy between fetal MRI and USG findings. The third case had a prediagnosis of thoracolumbar meningocele (10 mm) on USG, which was evaluated as a dermal cyst or dermoid cyst by fetal MRI. However, the final diagnosis after the postnatal evaluation was meningocele, and the infant underwent surgery on the second postnatal day. In the fourth case, USG had detected a horseshoe kidney, but fetal MRI interpreted it as normal.

In addition, prenatal imaging methods could not provide an actual diagnosis in four cases. These cases included one with germinal matrix bleeding, another with postnatal lissencephaly, one presenting with buphthalmia, and one with a low ear.

Discussion

We assessed the diagnostic accuracy of prenatal USG and MRI in 185 fetal congenital anomalies. In our study, the added value of fetal MRI to CNS anomalies was found to be 3.2%, much lower than in the literature. Studies have reported that fetal MRI has an additional contribution to USG of up to 16-22% in fetal CNS abnormalities (13-15). A recent systematic review and meta-analysis showed that in fetuses diagnosed with isolated ventriculomegaly, the incidence of CNS anomalies detected exclusively on MRI was lower than pre-

viously reported when a multiplanar ultrasound assessment of the fetal brain was conducted (16). In this study, the high success rate of prenatal USG may be due to several factors, including the expertise of the perinatologist performing the ultrasound examinations, optimal fetal positioning to assess anomaly, the use of transvaginal USG for vertex presentation, and the utilization of 3D and 4D imaging in combination with USG. The expertise and experience of the imaging team, along with the use of advanced imaging techniques, can greatly impact the diagnostic accuracy of USG in detecting CNS anomalies during prenatal care.

Consistent with previous studies, the most crucial contribution of MRI was in CNS anomalies, and ventriculomegaly was reported as the most common fetal MRI indication in CNS anomalies (17,18). In the meta-analysis that reviewed 27 articles (1184 cranial anomalies, in which neuro sonogram and fetal cranial MRI results were compared), the diagnosis was correct in 54% of the cases examined with USG and 80% with MRI, while 16% with USG and 6% with fetal MRI were misdiagnosed. The number of cases diagnosed correctly with both USG and MRI was 49% (19). In our study, 94% of the cases were diagnosed correctly with USG, 95.1% with MRI, 1.6% were misdiagnosed with USG, and 2.2% were misdiagnosed with fetal MRI. The number of cases in which both USG and MRI were diagnosed correctly was 91.9%, which was higher than the meta-analysis. In severe ventriculomegaly cases, both USG and fetal MRI had diagnosed all cases correctly, and fetal MRI had no additional contribution. However, in previous literature, fetal MRI has helped demonstrate secondary parenchymal brain damage that may occur due to ventricular compression and regional ischemia (20).

The research conducted by Conte et al. in their 2016 study

revealed that fetal MRI demonstrated a sensitivity of 88.9% in the diagnosis of midline anomalies (21). In our study, the sensitivity of MRI was 100% in midline anomalies, and its contribution to USG was 3.57%.

In our study, fetal MRI provided an additional contribution to the diagnosis in only one (4.3%) of twenty-three cases with posterior fossa anomaly. While ultrasound remains the preferred imaging modality for scanning these anomalies, in specific situations, MRI may offer several advantages (22,23). For instance, a study by Griffiths et al (2010) reported that antenatal findings changed in 44% of posterior fossa cases after fetal MRI (11). Nonetheless, re-evaluating the fetus using transvaginal neurosonography in vertex presentation could potentially enhance the success of ultrasound in detecting these abnormalities.

The sensitivity of fetal MRI in cortical developmental malformations has been reported to be 85% for polymicrogyria, 100% for schizencephaly, and 73% for heterotopia (24). In the present study, USG showed a sensitivity of 66.6% in detecting cortical anomalies, while MRI exhibited a higher sensitivity of 88.8% in the same context, and the contribution of fetal MRI was determined to be 22.2 percent. It is important to note that fetal cranial bone shadowing in the third trimester may potentially decrease the sensitivity of USG.

Fetal MRI and USG in evaluating NTD are also valuable for imaging the posterior fossa structures in imaging-restricted caudal lesions and in cases of Chiari II malformation (6). In our study, the compatibility between postnatal fetal findings and USG was 100%, fetal MRI was 93.7%, and fetal MRI did not provide any benefit to prenatal USG. In a study comparing prenatal transabdominal USG and MRI for meningomyelocele, the concordance of USG and MRI with postnatal imaging was reported as 79% and 82%, respectively (25). However, in the current study, the findings showed that prenatal USG was sufficient in the evaluation of NTD and was highly compatible with postnatal findings. These results reiterate that fetal MRI is not required in routine NTD evaluation. However, in some rare cases who want the pregnancy to continue; fetal MRI may be requested for evaluation of the amount of cerebellar herniation, referral to fetal surgery, postnatal prognosis prediction, and surgical planning.

According to the study conducted by Levine et al. (2003), which involved 74 fetuses, MRI provided additional information in 37.8% of the patients with thoracic abnormalities, beyond USG (26). In our study, we observed that fetal MRI contributed to the evaluation of thoracic anomalies in 14.2% of cases. Specifically, MRI helped determine that the hyperechoic mass in one case was being fed from the aorta, leading to a diagnosis of BPS. Based on the studies mentioned, it seems that the contribution of fetal MRI in evaluating thoracic anomalies varies between studies and may depend on the specific anomaly in question. Although routine fetal MRI is not

indicated for prenatal imaging of thoracic anomalies, in rare cases where fetal surgery is planned or when USG is inadequate for family counseling, additional imaging may be requested, taking into account the limitations and advantages of both methods.

A study investigating the complementary role of fetal MRI to sonography in bilateral urinary tract anomalies revealed that fetal MRI provided additional information in 31.2% of the cases (27). Manganaro et al. (2015) reported that fetal MRI provided additional information in 60.6% of fetuses with GIS anomalies, contradicted the USG diagnosis in 13%, and changed the diagnosis in 5.2% of cases (28). MRI has been shown to accurately characterize the intrapelvic and abdominal spread of sacrococcygeal tumors and compression on adjacent organs (29,30). In our study, it was observed that fetal MRI did not contribute additionally to USG in imaging neck masses, GUS, GIS, and sacrococcygeal teratomas, probably due to the low number of cases. In the diagnosis of fetal anomaly, USG always remains the necessary first imaging tool and often provides adequate imaging. However, in very rare cases, fetal MRI indications include: if an ex-utero intrapartum treatment (EXIT) procedure is planned which may allow time for upper airway intubation for neck masses, if poor anatomical evaluation cannot be performed due to severe oligohydramnios in urinary system abnormalities, or if fetal surgery is planned in obstructive urinary anomalies, and in the distribution of complex abdominal anomalies such as cloacal malformation. Additionally, the wide field of view with multi-shape images allows evaluation of MRI images by other specialized (surgeons, neurosurgeons, neurologists, urologists, etc.), and the team approach is useful for critical neurological fetal and postnatal surgical planning. It is also useful for families to review these details during the examination.

The present study has some notable limitations. Firstly, the sample size of 185 fetal anomalies may not be large enough to draw definitive conclusions, and a larger sample size would increase the study's statistical power and provide more robust findings. Our study shows the success of USG only in specific cases with suspected anomalies and cannot be generalized to the whole population. Furthermore, it is important to acknowledge that the study population was specifically referred for fetal MRI based on a suspected fetal anomaly diagnosis. This selective referral process could potentially introduce bias and impact the diagnostic accuracy and reliability of fetal MRI findings. Additionally, the study was conducted in a tertiary center with specific imaging protocols and experienced fetal medicine specialists, which limits the generalizability of the findings to other populations or settings with different imaging facilities, equipment, and protocols. Thus, caution should be tested when extrapolating the results of this study to broader populations or different study conditions, and further research with larger and more diverse samples is warranted to confirm the findings.

Conclusion

In fetuses undergoing detailed ultrasonography and specialized neurosonography by experienced professionals, the occurrence of additional fetal anomalies exclusively detected through MRI is now found to be lower than previously documented. Nonetheless, Fetal MRI is presently employed to offer supplementary information, advice, and assist in clinical decision-making. In the future, extensive prospective studies with standardized protocols for ultrasound imaging of the fetal brain, are necessary to better understand the true role of fetal MRI in cases where fetal neurosonography has already been performed.

Acknowledgment: We are grateful to all participants and their families who spent precious time participating in this research program. We are also thankful for the tireless efforts of the research team members.

Funding: This study did not receive a private grant from any public funding agency.

Ethics approval and consent to participate: All participants signed informed written consent before being enrolled in the study. The study was reviewed and approved by the ethics committee of Akdeniz University (Ethics approval reference number: KAEK-648 date 23 August 2023). All procedures were performed according to the Declaration of Helsinki.

Availability of data and materials: The data supporting this study is available through the corresponding author upon reasonable request. / The datasets and code used and/or analyzed during the current study are available from the corresponding author upon reasonable request.

Authors' contributions: EK and HK: Raised the presented idea and designed the study. EK, GAB, HK, and CYS: Participated in data analysis, interpretation, and draft revision. KK, CYS, and IIM: Critically reviewed the work for important intellectual content and approved the final published version.

Competing interests: The authors declare that they have no competing interests.

References

- Reddy UM, Filly RA, Copel JA; Pregnancy and Perinatology Branch, Eunice Kennedy Shriver National Institute of Child Health and Human Development, Department of Health and Human Services, NIH. Prenatal imaging: ultrasonography and magnetic resonance imaging. *Obstet Gynecol.* 2008;112(1):145-57. Doi:10.1097/01.AOG.0000318871.95090.d9. PMID: 185 91320
- Rathee S, Joshi P, Kelkar A, Seth N. Fetal MRI: A pictorial essay. *Indian J Radiol Imaging.* 2016;26(1):52-62. Doi:10.4103/0971-3026.178326. PMID: 27081224, PMCID: PMC4813075.
- Chung R, Kasprian G, Brugger PC, Prayer D. The current state and future of fetal imaging. *Clin Perinatol.* 2009; 36(3):685-99. Doi: 10.1016/j.clp.2009.07.004. PMID: 19732621.
- Masselli G, Vaccaro Notte MR, Zacharzewska-Gondek A, Laghi F, Manganaro L, Brunelli R. Fetal MRI of CNS abnormalities. *Clin Radiol.* 2020;75(8):640.e1-640.e11. Doi: 10.1016/j.crad.2020.03.035. PMID: 32349872.
- Levine D. Obstetric MRI. *J Magn Reson Imaging.* 2006; 24(1):1-15. Doi: 10.1002/jmri.20608. PMID:1673 64 91.
- Paladini D, Malinger G, Birnbaum R, Monteagudo A, Pilu G, Salomon LJ, et al. ISUOG Practice Guidelines (updated): sonographic examination of the fetal central nervous system. Part 2: performance of targeted neurosonography. *Ultrasound Obstet Gynecol.* 2021;57(4):661-71. Doi: 10.1002/uog.23616. Erratum in: *Ultrasound Obstet Gynecol.* 2022;60(4):591. PMID: 33734522.
- Malinger G, Paladini D, Haratz KK, Monteagudo A, Pilu GL, Timor-Tritsch IE. ISUOG Practice Guidelines (updated): sonographic examination of the fetal central nervous system. Part 1: performance of screening examination and indications for targeted neurosonography. *Ultrasound Obstet Gynecol.* 2020;56(3):476-84. Doi: 10.1002/uog.22145. Erratum in: *Ultrasound Obstet Gynecol.* 2022;60(4):591. PMID: 32870591.
- Salomon LJ, Alfirevic Z, Berghella V, Bilardo CM, Chalouhi GE, Da Silva Costa F, et al. ISUOG Practice Guidelines (updated): performance of the routine mid-trimester fetal ultrasound scan. *Ultrasound Obstet Gynecol.* 2022;59(6):840-56. Doi: 10.1002/uog.24888. Erratum in: *Ultrasound Obstet Gynecol.* 2022;60(4):591. PMID: 35592929.
- Glenn OA. MR imaging of the fetal brain. *Pediatr Radiol.* 2010;40(1):68-81. Doi: 10.1007/s00247-009-1459-3. PMID: 19937234, PMCID: PMC3229879.
- Gaglioti P, Oberto M, Todros T. The significance of fetal ventriculomegaly: etiology, short- and long-term outcomes. *Prenat Diagn.* 2009;29(4):381-8. Doi: 10.1002/pd.2195. PMID: 19184972.
- Griffiths PD, Reeves MJ, Morris JE, Mason G, Russell SA, Paley MN, et al. A prospective study of fetuses with isolated ventriculomegaly investigated by antenatal sonography and in utero MR imaging. *AJNR Am J Neuroradiol.* 2010;31(1):106-11. Doi: 10.3174/ajnr.A1767. PMID: 19762458, PMCID: PMC7964094.
- Achiron R, Achiron A. Development of the human fetal corpus callosum: a high-resolution, cross-sectional sonographic study. *Ultrasound Obstet Gynecol.* 2001;18(4): 343-7. Doi: 10.1046/j.0960-7692.2001.00512.x. PMID: 11778993.
- Rossi AC, Prefumo F. Additional value of fetal magnetic resonance imaging in the prenatal diagnosis of central nervous system anomalies: a systematic review of the literature. *Ultrasound Obstet Gynecol.* 2014;44(4):388-93. Doi: 10.1002/uog.13429. PMID: 24890732.
- Jarvis D, Mooney C, Cohen J, Papaioannou D, Bradburn M, Sutton A, et al. A systematic review and meta-analysis to determine the contribution of mr imaging to the diag-

- nosis of foetal brain abnormalities In Utero. *Eur Radiol.* 2017;27(6):2367-80. Doi: 10.1007/s00330-016-4563-4. PMID: 27655301, PMCID: PMC5408056.
15. Scala C, Familiari A, Pinas A, Papageorgiou AT, Bhide A, Thilaganathan B, et al. Perinatal and long-term outcomes in fetuses diagnosed with isolated unilateral ventriculomegaly: systematic review and meta-analysis. *Ultrasound Obstet Gynecol.* 2017;49(4):450-9. Doi:10.1002/uog.15943. PMID: 27091707.
 16. Di Mascio D, Sileo FG, Khalil A, Rizzo G, Persico N, Brunelli R, et al. Role of magnetic resonance imaging in fetuses with mild or moderate ventriculomegaly in the era of fetal neurosonography: systematic review and meta-analysis. *Ultrasound Obstet Gynecol.* 2019;54(2):164-71. Doi: 10.1002/uog.20197. PMID: 30549340.
 17. Perrone A, Savelli S, Maggi C, Di Pietro L, Di Maurizio M, Tesei J, et al. Magnetic resonance imaging versus ultrasonography in fetal pathology. *Radiol Med.* 2008; 113(2):225-41. English, Italian. Doi: 10.1007/s11547-008-0242-0. PMID: 18386124.
 18. Rajeswaran R, Chandrasekharan A, Joseph S, Venkata Sai PM, Dev B, Reddy S. Ultrasound versus MRI in the diagnosis of fetal head and trunk anomalies. *J Matern Fetal Neonatal Med.* 2009;22(2):115-23. Doi: 10.1080/14767050802488238. PMID: 19085633.
 19. van Doorn M, Oude Rengerink K, Newsum EA, Reneman L, Majoie CB, Pajkrt E. Added value of fetal MRI in fetuses with suspected brain abnormalities on neurosonography: a systematic review and meta-analysis. *J Matern Fetal Neonatal Med.* 2016;29(18):2949-61. Doi: 10.3109/14767058.2015.1109621. PMID: 26592136.
 20. Ortega E, Muñoz RI, Luza N, Guerra F, Guerra M, Vio K, et al. The value of early and comprehensive diagnoses in a human fetus with hydrocephalus and progressive obliteration of the aqueduct of Sylvius: Case Report. *BMC Neurol.* 2016;16:45. Doi: 10.1186/s12883-016-0566-7. PMID: 27067115, PMCID: PMC4828774.
 21. Conte G, Parazzini C, Falanga G, Cesaretti C, Izzo G, Rustico M, et al. Diagnostic Value of Prenatal MR Imaging in the Detection of Brain Malformations in Fetuses before the 26th Week of Gestational Age. *AJNR Am J Neuroradiol.* 2016;37(5):946-51. Doi: 10.3174/ajnr.A4639. PMID: 26721771, PMCID: PMC7960315.
 22. O'Connor SC, Rooks VJ, Smith AB. Magnetic resonance imaging of the fetal central nervous system, head, neck, and chest. *Semin Ultrasound CT MR.* 2012;33(1):86-101. Doi: 10.1053/j.sult.2011.10.005. PMID: 22264906.
 23. Zhao D, Cai A, Zhang J, Wang Y, Wang B. Measurement of normal fetal cerebellar vermis at 24-32 weeks of gestation by transabdominal ultrasound and magnetic resonance imaging: A prospective comparative study. *Eur J Radiol.* 2018;100:30-5. Doi: 10.1016/j.ejrad.2018.01.013. PMID: 29496076.
 24. Glenn OA, Cuneo AA, Barkovich AJ, Hashemi Z, Bartha AI, Xu D. Malformations of cortical development: diagnostic accuracy of fetal MR imaging. *Radiology.* 2012;263(3):843-55. Doi: 10.1148/radiol.12102492. PMID: 22495681, PMCID: PMC3359515.
 25. Aaronson OS, Hernanz-Schulman M, Bruner JP, Reed GW, Tulipan NB. Myelomeningocele: prenatal evaluation--comparison between transabdominal US and MR imaging. *Radiology.* 2003;227(3):839-43. Doi: 10.1148/radiol.2273020535. PMID: 12714679.
 26. Levine D, Barnewolt CE, Mehta TS, Trop I, Estroff J, Wong G. Fetal thoracic abnormalities: MR imaging. *Radiology.* 2003;228(2):379-88. Doi: 10.1148/radiol.2282020604. PMID: 12821772.
 27. Cassart M, Massez A, Metens T, Rypens F, Lambot MA, Hall M, et al. Complementary role of MRI after sonography in assessing bilateral urinary tract anomalies in the fetus. *AJR Am J Roentgenol.* 2004;182(3):689-95. Doi: 10.2214/ajr.182.3.1820689. PMID: 14975971.
 28. Manganaro L, Saldari M, Bernardo S, Vinci V, Aliberti C, Sollazzo P, et al. Role of magnetic resonance imaging in the prenatal diagnosis of gastrointestinal fetal anomalies. *Radiol Med.* 2015;120(4):393-403. Doi: 10.1007/s11547-014-0464-2. PMID: 25348138.
 29. Roman AS, Monteagudo A, Timor-Tritsch I, Rebarber A. First-trimester diagnosis of sacrococcygeal teratoma: the role of three-dimensional ultrasound. *Ultrasound Obstet Gynecol.* 2004;23(6):612-4. Doi: 10.1002/uog.1055. PMID: 15170807.
 30. Danzer E, Hubbard AM, Hedrick HL, Johnson MP, Wilson RD, Howell LJ, et al. Diagnosis and characterization of fetal sacrococcygeal teratoma with prenatal MRI. *AJR Am J Roentgenol.* 2006;187(4):W350-6. Doi: 10.2214/AJR.05.0152. PMID: 16985105.