

# Abdominal Wall Endometriosis Following Cesarean Section: Report of a Case

Selçuk ERKİLİNÇ<sup>1</sup>, Coşkun ÜMİT<sup>1</sup>, Gamze ERKİLİNÇ<sup>2</sup>, İrfan ÖZER<sup>1</sup>, Ali İrfan GÜZEL<sup>1</sup>, Melike DOĞANAY<sup>1</sup>

Ankara, Turkey

Endometriosis is the presence of functional endometrial tissue outside the uterus. Abdominal wall endometriosis is the one of the rarest site of extra pelvic endometriosis (AWE). We herein report the clinical characteristics of a 29 year's old (G2P2) woman with abdominal wall endometriosis, 21 months after the last cesarean section. A total excision of the mass was performed and final histopathology of the mass was reported as endometriosis. We recommend taking into consideration this rare condition especially in women presenting painful mass near the scar with previous caesarean section.

**Key Words:** Caesarean, Abdominal wall, Endometriosis

Gynecol Obstet Reprod Med 2014;20:62-63

## Introduction

Abdominal wall endometriosis (AWE) is defined as endometrial tissue superficial to the peritoneum and is associated with a history of surgical procedures such as cesarean delivery, hysterotomy, hysterectomy, episiotomy, ectopic pregnancies, and laparoscopy, among others.<sup>1</sup> Simply it may be described as growth of endometrial gland and stroma outside the uterus.<sup>2</sup> Abdominal wall endometriosis is the one of the rarest site of extra pelvic endometriosis (AWE).<sup>3</sup>

The explanation of this pathogenic condition is the "iatrogenic direct implantation theory," which suggests that endometrial cells escape through an incision made in the uterus during the surgical procedure and are implanted within the abdominal wound. AWE that follows previous caesarean section has an incidence of 0.03%-0.4%.<sup>1</sup>

In this case report, we aimed to evaluate the clinical characteristics of a case of AWE following cesarean section surgically managed and successfully treated.

## Case Report

A 29 years old woman (G2P2) was admitted to our hospi-

tal with the complaint of lower abdominal pain. She was a smoker and had a history of two previous cesarean section and had the last caesarean sections 21 months ago. On physical examination of abdominal wall a semi solid, tender and painful mass was encountered.

An ultrasound and a computerized tomography imaging techniques performed preoperatively we detected a 21x14 mm heterogeneous hypoechoic and semisolid mass (Figure 1) with internal echoes 15 mm deep from the skin. The computerized tomography imaging revealed a 20 mm nodular lesion showing late phase opafication on abdominal wall.

After the approval of the patient total excision of the mass followed by a fine needle biopsy both under local anesthesia without damaging the rectus abdominis muscle was performed. Preoperative and postoperative histopathological examination of the resected mass was endometriosis (Figure 2).

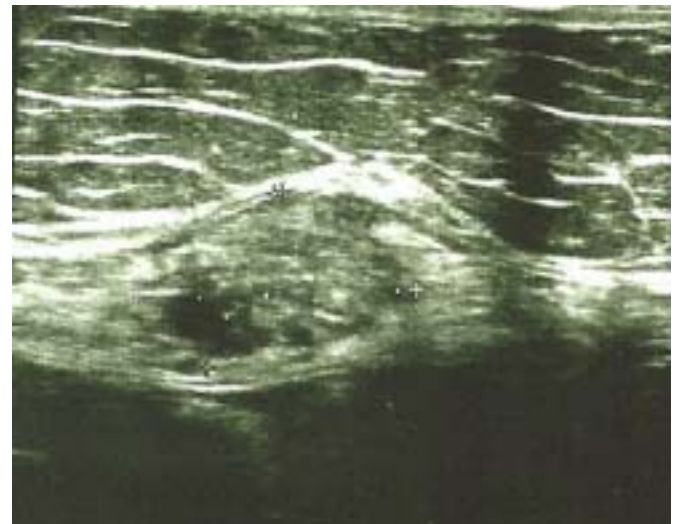

Figure 1: A 21x14 mm heterogen hypoechoic and semisolid mass with internal echoes 15 mm deep from the skin

<sup>1</sup> Zekai Tahir Burak Women's Health Training and Education Hospital, Ankara

<sup>2</sup> Numune Training and Research Hospital, Department of Pathology, Ankara

Address of Correspondence: Ali İrfan Güzel  
Zekai Tahir Burak Women's Health  
Training and Education Hospital  
Ankara, Turkey  
alijnk@hotmail.com

Submitted for Publication: 24. 07. 2013

Accepted for Publication: 22. 11. 2013

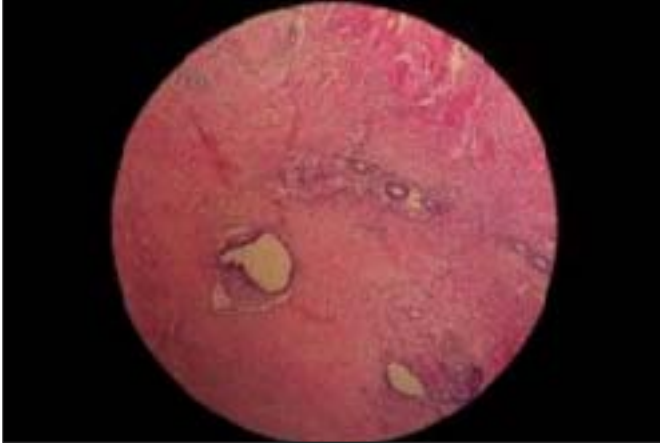


Figure 2: Microscopic appearance of abdominal wall endometriosis shows endometriotic glands near fibromuscular stroma

## Discussion

The majority of the AWE is associated with a history of surgical procedures such as cesarean delivery, hysterotomy, hysterectomy, episiotomy, ectopic pregnancies, and laparoscopy, among others. AWE that follows previous caesarean section has an incidence of 0.03%-0.4%.<sup>1</sup>

Nirula<sup>4</sup> explained the pathogenetic mechanism as inoculation of the surgical wound with endometrial cells during the surgery and subsequently proliferation of these cells in order to form endometrioma in the scar by hormonal stimuli.

In general, the most evident clinical manifestation of endometriosis is a painful subcutaneous mass together with a cyclic pain associated with menses.<sup>5</sup> Diagnosis of AWE is easily when pain occurs cyclically and is generally misdiagnosed when the complaint is not cyclic. In our case, the main symptom was a painful mass.

Owing to its low cost and practicality, ultrasonography is the most commonly used investigational procedure for abdominal masses. If the diameter of the endometrioma is more than 4 cm, however, MRI provides more precise topographic information.<sup>1</sup> In the presented case we used both ultrasonography and computerized tomography as imaging techniques. Savelli et al.<sup>7</sup> published that AWE cannot be distinguished from invasive abdominal masses by CT. In our case computerized tomography did not supply any additional knowledge as in literature.

The accuracy rate of preoperative diagnosis reported to be from 20% to 50%.<sup>1</sup> For this reason additional diagnostic procedures may be necessary. We performed a fine needle biopsy for a possible diagnostic pitfall. Fine-needle aspiration cytology is a minimally invasive procedure that can provide a diag-

nosis and eliminate the possibility of malignancy; however, its use remains controversial because theoretically it has the potential to implant endometrial cells further at the puncture site.<sup>1</sup>

AWE should be treated with total excision of the mass under anesthesia. If there are signs of pelvic endometriosis oral contraceptives, danazol or GnRH analogues may be added to the therapy.<sup>6</sup> We also performed total excision of the masses under local anesthesia in our case.

As a result, AWE must be considered as a possible diagnosis for females of reproductive age complaining of mass or pain in or around the abdominal scar after a surgery, such as cesarean delivery.

## Sezaryen Sonrası Gelişen Abdominal Duvar Endometrioması: Olgu Sunumu

Endometriosis fonksiyonel endometriyal dokunun uterus dışında bulunmasıdır. Abdominal duvar endometrioması ekstrapelvik endometriyomaların en nadir görüldüğü yerlerden biridir. Bu olguda 29 yaşında, (G2P2) 21 ay önce sezaryen yapılan abdominal duvar endometriomasının klinik özelliklerini sunmaktayız. Sezaryen öyküsü bulunan ve sezaryen skar hattında ağrılı kitlesi bulunan hastalarda ayırıcı tanıda abdominal duvar endometrioması düşünülmelidir.

**Anahtar Kelimeler:** Sezaryen, Karın duvarı, Endometriosis

## References

1. Ding Y, Zhu J. A retrospective review of abdominal wall endometriosis in Shanghai, China. *Int J Gynaecol Obstet* 2013;121(1):41-4.
2. Koger KE, Shatney CH, Hodge K, McClenathan JH. Surgical scar endometrioma. *Surg Gynecol Obstet* 1993;177(3):243-6.
3. Comanescu M, Annaratone L, D'Armento G, Cardoso G, Sapino A, Bussolati G. Critical steps in tissue processing in histopathology. *Recent Pat DNA Gene Seq* 2012;6 (1): 22-32.
4. Nirula R, Greaney GC. Incisional endometriosis: an underappreciated diagnosis in general surgery. *J Am Coll Surg* 2000;190(4):404-7.
5. Bektas H, Bilsel Y, Sari YS, et al. Abdominal wall endometrioma; a 10-year experience and brief review of the literature. *J Surg Res* 2010;164 (1):e77-81.
6. Chun JT, Nelson HS, Jr., Maull KI. Endometriosis of the abdominal wall. *South Med J* 1990;83(12):1491-2.
7. Savelli L, Manuzzi L, Donato ND, et al. Endometriosis of the abdominal wall: ultrasonographic and Doppler characteristics. *Ultrasound Obstet Gynecol* 2012;39:336-40.