

Peripartum Ruptured Uterine Angioleiomyoma

Nora MOHAMED¹, Ayman ALMASALMA²

Muscat, Oman

ABSTRACT

Uterine angioleiomyoma is a rare entity. Angioleiomyoma is a benign vascular tumor that originates from the blood vessels. Although exceptionally they can be found in the uterus, they are commonly reported in the lower extremity. Preoperative diagnosis is tricky. We are publishing this case to highlight uterine contractions as a possible cause of the peripartum rupture.

The patient was in her fourth pregnancy, with a history of three vaginal deliveries. She presented to the emergency department in our hospital with labor pain, at 39 weeks of gestation, and was admitted to the labor unit in active labor. She had an uneventful vaginal delivery with a good neonatal outcome. After delivery, the patient complained of abdominal pain, shoulder tip pain, and abdominal distention.

Examination revealed a tender mass felt on the left side of the uterus up to the left hypochondriac region, contracted uterus, and normal lochia. A CT (computed tomography) scan was carried out and was remarkable for a left-sided, mixed-density, abdominopelvic lesion, measuring 18×12×9 cm, and a moderate amount of hemoperitoneum. Intraoperatively there was 1 liter of free blood, ruptured left-sided, subserous myoma connected to a 20×15 cm hematoma. A myomectomy was carried out. Histopathology reported an angioleiomyoma with symplastic-type cells.

Although infrequent, complicated angioleiomyoma should be suspected in the differential diagnosis of abdominopelvic hematoma in patients with uterine fibroids.

Keywords: Hematoma, Peripartum, Uterine angioleiomyoma

Gynecol Obstet Reprod Med 2023;29(3):219-222

Introduction

Angioleiomyomas are scarce, nonmalignant vascular tumors that originate from the tunica media in the blood vessels. They are commonly reported in the lower extremity, although they can be found anywhere in the body. Preoperative diagnosis is difficult, and diagnosis is made almost always after a histological examination of the specimen (1).

Uterine angioleiomyoma is a rare entity with 16 cases reported in the literature, to our knowledge (2). Sikora-Szczeńniak et al. reported uterine Angioleiomyomas at 3.4 to 4 in 1000 cases of uterine leiomyoma (3).

We are reporting this case to decrease the threshold for suspicion of uterine angioleiomyoma in postpartum patients with known fibroids and a coincided pelvic-abdominal hematoma.

Case presentation

The patient was 35 years old. Gravida four para three. Previous vaginal deliveries. She had no follow-up pre-pregnancy, hence the diagnosis of fibroid was not previously established. She presented to the emergency department in North Area Armed Forces Hospital at term with contractions. She was in active labor, therefore, was admitted to the labor ward. She had an uneventful, smooth vaginal birth with a good neonatal outcome. After delivery, the patient complained of abdominal pain, shoulder tip pain, and abdominal distention. On examination, her vital signs were Bp:113/78 P:117 b/Min, abdomen revealed a tender mass felt on the left side of the uterus up to the left hypochondriac region, contracted uterus, and normal Lochia. A CT (computed tomography) scan was carried out. It was remarkable for a left-sided, mixed-density abdominopelvic lesion, with no enhancement after contrast

¹ Obstetrics & Gynecology department Sultan Qaboos University Hospital Muscat, Oman

² Obstetrics & Gynecology department, North area armed forces hospital, Hafar Albatin, Saudi Arabia.

Address of Correspondence: Nora Mohamed
Obstetrics & Gynecology department
Sultan Qaboos University Hospital,
Muscat, Oman
noraamohamed@outlook.com

Submitted for Publication: 28.02.2022 Revised for Publication: 01.08.2022

Accepted for Publication: 09.10.2022 Online Published: 20.10.2022

ORCID IDs of the authors: NM: 0000-0002-8033-1816

AA: 0000-0001-9816-7412

Quick Response Code:	Access this article online
	Website: www.gorm.com.tr
	e-mail: info@gorm.com.tr
	DOI:10.21613/GORM.2022.1300

How to cite this article: Mohamed N. and Almasalma A. Peripartum Ruptured Uterine Angioleiomyoma. *Gynecol Obstet Reprod Med* 2023;29(3):219-222



Copyright© 2023. Mohamed et al. This article is distributed under a Creative Commons Attribution 4.0 International License.

administration, measuring 18×12×9 cm and a moderate amount of hemoperitoneum (Figure 1), raising suspicion of a sizable broad ligament hematoma. The patient agreed to laparotomy; after extensive counseling and an explanation of her clinical course and possible complications. Intraoperatively, there was free intra-abdominal bleeding around 1000 mL, ruptured left-sided, subserous myoma connected to a 20×15 cm hematoma (Figure 2). We found myomectomy easy and suitable for the case; the patient had a stable postoperative course and received five packed RBC units. She was released home in good condition and followed in the outpatient department until she was discharged from the clinic. One-year phone follow-up provided no recurrence or gynecological complaint.

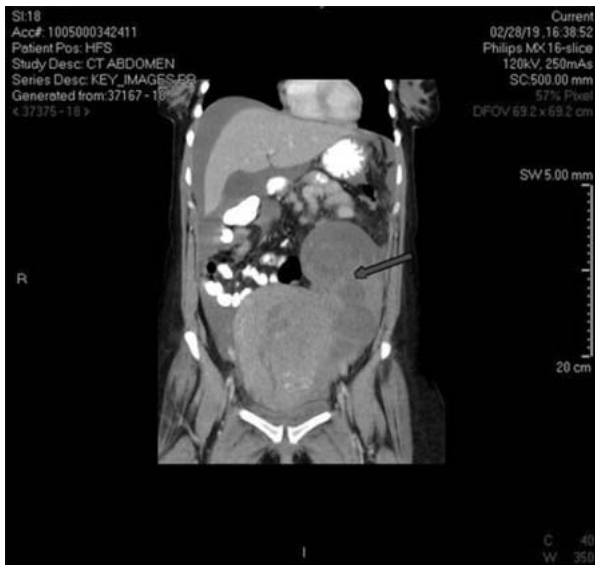

Figure 1: Abdominal CT scan shows left-sided, mixed density, abdominopelvic lesion. Coronal view

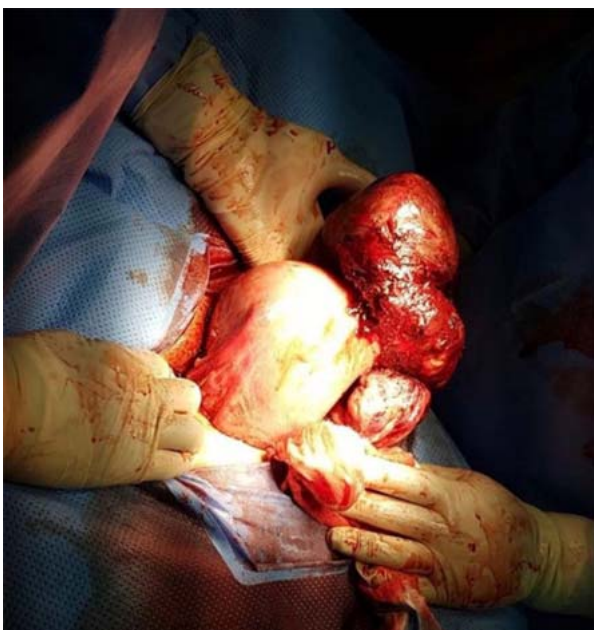

Figure 2: Intra-operative left-sided ruptured subserous myoma with attached hematoma

Histopathology grossly described a hemorrhagic fragmented whitish-deep brown tissue measuring 15×14×10 cm. Cut sections show a whitish hemorrhagic surface and hematoma. Microscopically, the cut sections show a vascularized tumor with attached hematoma; the mass is mainly composed of interlacing smooth muscle fascicles (Figure 3) with mitosis less than 1/10HPF with areas of myxomatous changes and symplastic-like cells. Blood vessels were numerous, of variable sizes, and had remarkable endothelial lining (Figure 4).

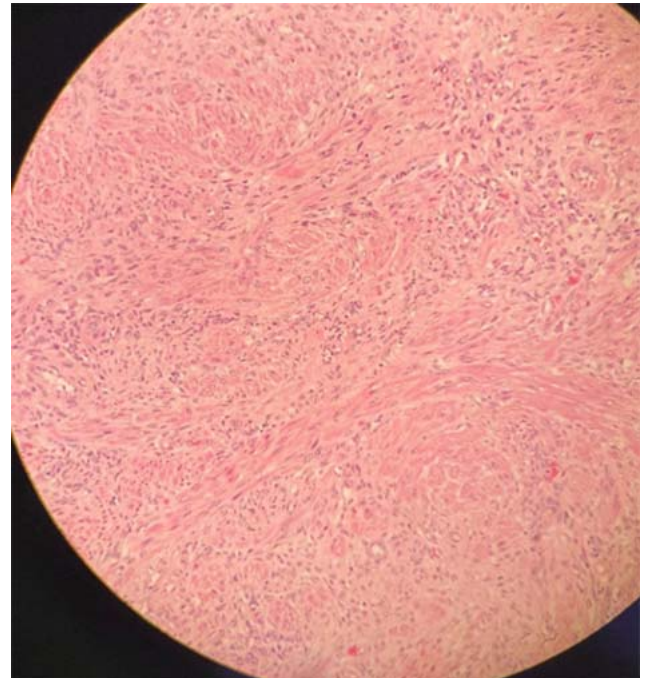


Figure 3: Microscopic section shows interlacing smooth muscle fascicles with foci of blood vessels

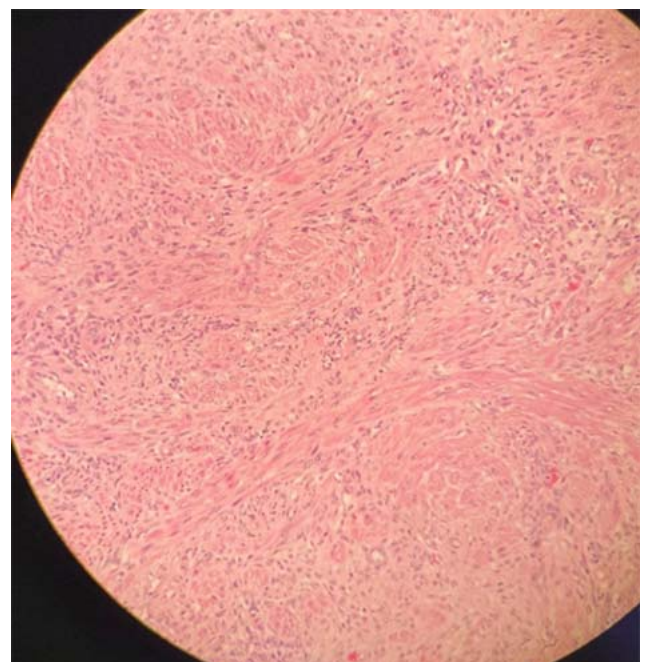


Figure 4: Microscopic section shows leiomyoma with prominent vasculature.

No evidence of malignancy was detected, and the histopathologist established the diagnosis of angioleiomyoma with symplastic-type cells.

Consent for using data was obtained from the participant. The ethics committee approval was acquired for publication. (30/4/2020 #31) The report was written in accordance with the declaration of Helsinki.

Discussion

The recorded age group in uterine angioleiomyoma is between the third and the sixth decade. The presenting symptoms and complications in patients with angioleiomyoma of the uterus vary widely, including but not limited to an abdominal mass, abdominal pain, and menorrhagia (4). Rarely consumptive coagulopathy can occur, either due to ischemic degeneration, as seen in handler et al. (5), or after myomectomy (6). Like our case, a uterine rupture with or without pregnancy is the most compromising complication of uterine angioleiomyoma, mandating half the patients to receive a blood transfusion (7).

The presence of pronounced, tortuous vessels, and sand-like enhancing structures within a uterine mass with prominent uterine vessels hypertrophy and bilateral pelvic varicosity in computerized tomography of patients with uterine tumors can indicate uterine angioleiomyoma despite the difficulty of preoperative diagnosis (8). These findings make CT fundamental in the evaluation of complex uterine masses, especially in stable patients.

On histological examination, our case showed features of a leiomyoma with bizarre nuclei. Still, it didn't classify as one, but rather as an angioleiomyoma due to the latter's prominent findings at the time of the study. A publication suggested adding angioleiomyoma to the world health organization classification as a separate benign entity of female genital tract tumors (9).

Histopathological classification of angioleiomyoma includes three subdivisions. First is solid tumors consisting of an array of compact, smooth muscles intersecting with numerous small, slit-like vascular branches. Second is cavernous tumors with a lesser amount of smooth muscles, and dilated vessels, the vascular compartment is difficult to demarcate from the muscular bundle. The third is venous tumors composing thick-walled vascular channels that can be easily distinguishable from the less compacted smooth muscle bundles (1). Other microscopic findings may include myxomatous changes, as was found in our case, hyaline changes, and focal lymphocytic infiltrates (1).

Tumor edges infiltration, necrosis, atypical nuclei, or marked mitosis mandate extensive sampling to exclude leiomyosarcoma (10).

Conclusion

Although angioleiomyoma is considered to be an uncommon benign tumor, it can be associated with severe complications. Intrapartum uterine contractions could be a cause for the rupture of uterine angioleiomyoma. Management is sufficient with complete removal by myomectomy, including a robot-assisted laparoscopic resection of the myoma, or total abdominal hysterectomy with or without removal of the appendages. Yet further research is still needed to prove this conjecture (2,11,12).

Acknowledgments: I want to express my great appreciation to the histopathology department with special thanks to Dr. Shawqi Othman and Nidaa who helped with taking the slides and photographs.

Conflict of interest: The authors declare that they have no competing interests.

Funding sources: None.

Author's contribution: NM Contributed to the conception, design of the report, and acquisition of data. NM: and AA: Contributed to the interpretation of data. NM: Drafted the article. AA: Helped revise it critically for important intellectual content, all authors gave the final approval of the version to be submitted.

References

- Hachisuga T, Hashimoto H, Enjoji M. Angioleiomyoma. A clinicopathologic reappraisal of 562 cases. *Cancer*. 1984;54(1):126-30. Doi: 10.1002/1097-0142(19840701)54:1<126::aid-cnrcr2820540125>3.0.co;2-f. PMID: 6722737.
- Diwaker P, Pradhan D, Garg G, Bisaria D, Gogoi K, Mohanty SK. Uterine angioleiomyoma: A rare variant of uterine leiomyoma--A case report and literature review. *J Cancer Res Ther*. 2015;11(3):649. Doi: 10.4103/0973-1482.138127. PMID: 26458617.
- Sikora-Szcześniak DL. Uterine angioleiomyoma - a rare variant of uterine leiomyoma: review of literature and case reports. *Prz Menopauzalny*. 2016;15(3):165-9. doi: 10.5114/pm.2016.63496. PMID: 27980528, PMCID: PMC5137480.
- Garg G, Mohanty SK. Uterine angioleiomyoma: a rare variant of uterine leiomyoma. *Arch Pathol Lab Med*. 2014;138(8):1115-8. doi: 10.5858/arpa.2013-0315-RS. PMID: 25076303.
- Handler M, Rezai F, Fless KG, Litinski M, Yodice PC. Uterine angioleiomyoma complicated by consumptive coagulopathy. *Gynecol Oncol Case Rep*. 2012;2(3):89-91. Doi: 10.1016/j.gynor.2012.03.005. PMID: 24371629, PMCID: PMC3860903.
- Kamath MS, Acharya M, Kamath V, Aleyamma TK. Disseminated intravascular coagulation after myomectomy: a case report and review of literature. *Int J Infertility Fetal Med*. 2013;4(1):31-3. Doi: 10.5005/jp-journals-

- 10016-1057.
7. Junainah EM, Hammadi WA, Huwait HF, ArefAlbezrah NK, Bakr AS, Althaher F, et al. Uterine angioleiomyoma, A distinct variant of uterine leiomyoma. *Allied J Clin Pathol.* 2017;1(1):1-3.
 8. Pierro A, Rotondi F, Cilla S, De Ninno M, Mattoni M, Berardi S, et al. Giant angioleiomyoma of uterus: A case report with focus on CT imaging. *Radiol Case Rep.* 2018;13(2):371-5. Doi: 10.1016/j.radcr.2018.01.015. PMID: 29904475, PMCID: PMC6000078.
 9. Sahu L, Tempe A, Agrawal A. Angioleiomyoma of uterus. *J Obstet Gynaecol.* 2012;32(7):713-4. Doi: 10.3109/01443615.2012.702148. PMID: 22943735.
 10. Laxminarayana B, Anwar Miya M, Venishetty H, Raghuram Mohan S, Sandhya Anil S, Sandhya Rani H, Chandra Sekhar S. Angioleiomyoma of uterus-a rare case report. *IOSR Journal of Dental and Medical Sciences.* 2015;14(10):60-3. Doi: 10.9790/0853-1410106063
 11. McCluggage WG, Boyde A. Uterine angioleiomyomas: a report of 3 cases of a distinctive benign leiomyoma variant. *Int J Surg Pathol.* 2007;15(3):262-5. Doi: 10.1177/1066896907302226. PMID: 17652533.
 12. Kim H, Lee JJ, Choi Y, Lee M, Hwang HJ, Chung YJ, Cho HH, et al. Successfully removed uterine angioleiomyoma by robot-assisted laparoscopic myomectomy. *Obstet Gynecol Sci.* 2018;61(3):425-429. Doi: 10.5468/ogs.2018.61.3.425. PMID: 29780788, PMCID: PMC5956129.