

# Spontaneous Rupture of Renal Cell Carcinoma in Pregnancy: A Case Report

Mohamed ZAKIELDAHSHOURY<sup>1</sup>, Hassaan A. GAD<sup>1</sup>, Salah AHMED<sup>1</sup>

Aswan, Egypt

## ABSTRACT

Renal cell carcinoma is the most common type of malignancy in pregnancy. Rupture of renal cell carcinoma is not uncommon. The diagnosis of renal cell carcinoma is often delayed as the clinical presentation might resemble other pregnancy-related disorders or asymptomatic in most cases and a complete ultrasonographic examination of the abdomen is not a part of the routine obstetric evaluation. We report a rare case with spontaneous rupture of renal cell carcinoma in 20 years old in full-term pregnancy primigravida presented by hypertensive disorder and severe abdominal pain with massive retro peritoneum collection, radical nephrectomy was done and the patient life was saved.

**Keywords:** Kidney, Pregnancy, Renal cell carcinoma, Renal ruptures

*Gynecol Obstet Reprod Med.* 2023;29(2):143-145

## Introduction

Urological malignancy in pregnancy is a rare event. It is only (13/1,000,000 pregnancies) (1) of estimated all types of neoplasm during pregnancy 0.1% (2). Renal cell carcinoma is the most common renal malignancy accounting for almost 90-95% of all primary renal neoplasms (3). High parity and hormonal factors are potential risk factors (4). Diagnosis of renal cell carcinoma during pregnancy comes late because it is asymptomatic or sometimes presents similar to the common symptoms of pregnancy (5). The possibility of malignancy during pregnancy may not be kept in mind (5). It is difficult to identify renal malignancy during pregnancy until the advanced stage of pregnancy because in most cases a complete

ultrasound of the abdomen is not a part of the routine obstetric evaluation (5). We report a rare case of spontaneous rupture of a huge renal tumor during a full-term pregnant female. A multidisciplinary approach is mandatory in the diagnosis and management of renal cell carcinoma in pregnancy.

## Case Report

A 20-years-old primigravida female presented at 38th weeks of gestation. She was referred to Aswan university hospital from a rural area. The patient complained of hypertensive disorder during pregnancy. The clinical and radiological obstetric evaluation revealed a viable single intrauterine fetus. The delivery was by cesarean section. The patient developed acute abdominal pain and distention shortly postoperative. Abdominal ultrasonography revealed a huge left retroperitoneum hematoma. A computed tomography scan revealed a hugely enlarged left kidney with heterogeneous density which was surrounded by a large retroperitoneum perinephric hematoma (Figure 1).

Immediate laparotomy was done with exposure of the left retroperitoneal space, control of the left renal pedicle then removal of the necrotic tissues and blood clots. The anterior wall of the kidney was ruptured. Radical nephrectomy was the line of treatment (Figure 2). The histopathological study from kidney tissue revealed clear cell carcinoma GII with a wide area of necrosis, focal papillary features, free tumor margin, and focal interstitial nephritis. The patient survived with a smooth post-operative course. Informed consent was obtained from the patient for the publication of the case report

<sup>1</sup> Department of Urology, Aswan University Hospital, Aswan, Egypt


Address of Correspondence: Mohamad Zaki El-dahshoury  
Prof. of Urology & Reconstructive Urethral  
Surgery Urology Dept, Aswan University  
Aswan, Egypt  
mohamed.zaki@med.aswu.edu.eg.

Submitted for Publication: 15.10.2021 Revised for Publication: 18.10.2021

Accepted for Publication: 13.06.2022 Online Published: 23.06.2022

ORCID IDs of the authors: MZ: 0000-0002-7062-229X

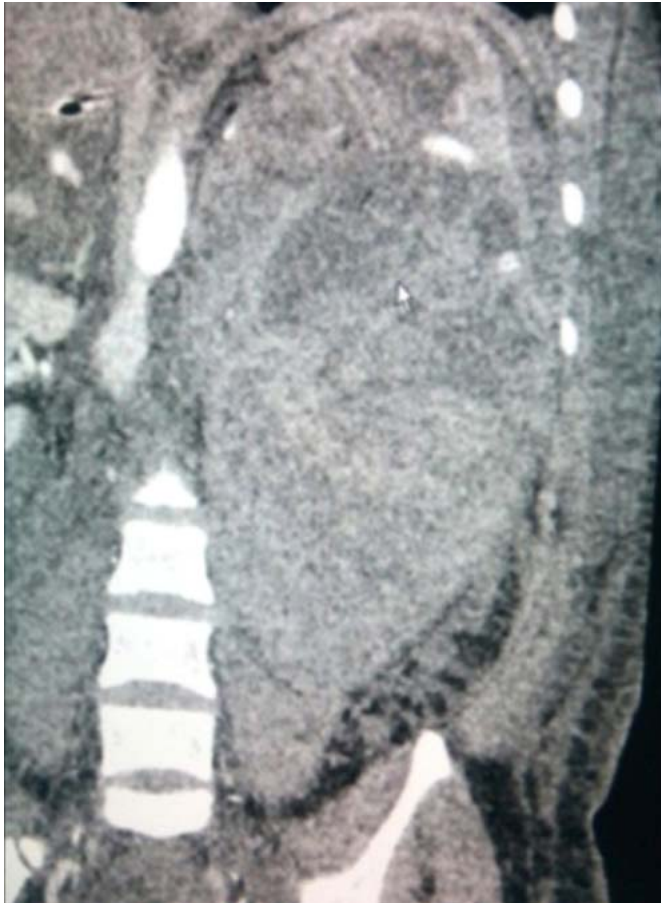HAG: 0000-0001-8379-1028 SA: 0000-0002-5969-8795

Quick Response Code:	Access this article online
	Website: <a href="http://www.gorm.com.tr">www.gorm.com.tr</a>
	e-mail: <a href="mailto:info@gorm.com.tr">info@gorm.com.tr</a>
	DOI:10.21613/GORM.2022.1266

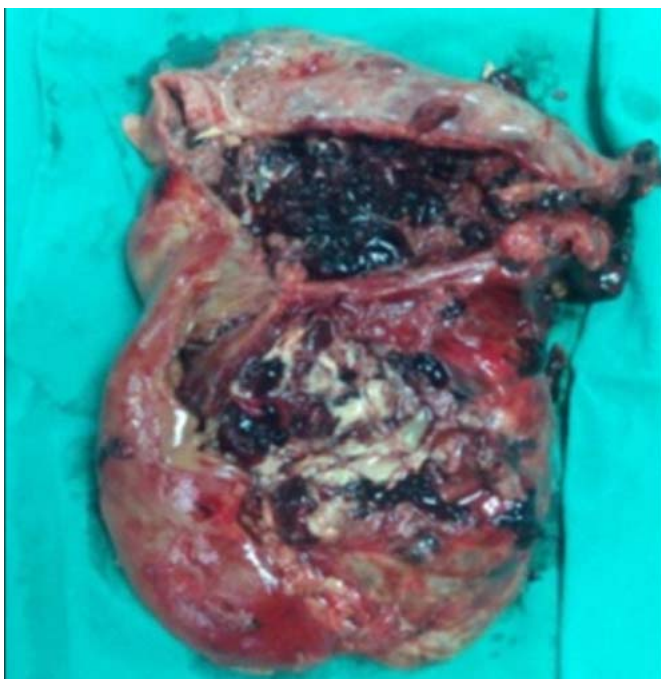
**How to cite this article:** Zakielhahshoury M, Gad HA, Ahmed S. Spontaneous Rupture of Renal Cell Carcinoma in Pregnancy: A Case Report. *Gynecol Obstet Reprod Med* 2023;29(2):143-145



Copyright© 2023. Zakielhahshoury et al. This article is distributed under a Creative Commons Attribution 4.0 International License.



**Figure 1:** CT scan of abdomen



**Figure 2:** Nephrectomy specimen

## Discussion

Renal cell carcinoma is a common type of urological malignancy in pregnancy, it represents 3% of the adult population, and its peak is after the 5th decade of life (5). The classi-

cal triad of hematuria, flank mass, and flank pain are less commonly presented (26%). The main reported symptoms are pain (50% of cases), hematuria (47%), and hypertension (18%). Infrequent presentations such as hemolytic anemia, hypercalcemia, and rupture of tumor cyst were also reported (6). Diagnosis of RCC is more frequently made incidentally during ultrasound examinations performed for other reasons (7). The safest diagnostic imaging test during pregnancy is ultrasound, with no radiation risk because of teratogenicity or carcinogenesis. Ultrasound has a sensitivity of (82%) to detect lesions of size 2×3 cm but it is operator-dependent (8). MRI is the first choice for investigation in cases of malignancy in pregnancy and can replace CT in non-pregnant. Plasma renin level can be used as a screening test in young hypertensive pregnant patients with suspicion of kidney cancer (2). Doppler ultrasound can be used to assess the function of the contralateral kidney (9) and renal scintigraphy may be needed to assess renal function reserve before nephrectomy (10). Management guidelines for RCC in pregnancy are not standardized and the decision is individualized according to the time of diagnosis, trimester stage, stage of the malignancy, and the safety of both the mother and the fetus. The management needs a multidisciplinary approach and team discussions for decision making including urologists, gynecologists, oncologists, and radiologists, the mother's choice and her wishes are always important and respected.

Radical or nephron-sparing surgery remains a gold standard part of the management of RCC, even in metastatic disease as renal neoplasm is slowly growing with a doubling time of more than 500 days (11). If the diagnosis of RCC is late in pregnancy it will be reasonable to wait till after delivery. In the 2<sup>nd</sup> trimester, surgery could be delayed till fetal lung maturation by the 28<sup>th</sup> week of gestation or even postpartum in some reports (12). If the diagnosis of RCC is in 1<sup>st</sup> trimester, it will be advisable to wait till 2<sup>nd</sup> trimester or have immediate surgery despite the small increased risk of miscarriage (13). A solid mass needs immediate surgery by either laparoscopic or open surgery, transperitoneal or retroperitoneal governed by the tumor site, size, and the expertise of the surgical team.

No correlation was reported between tumor size and frequency of rupture. Rupture of the mass may be due to extension of the mass to the renal vein, causing an elevation in venous pressure secondary to tumor emboli or direct invasion of the renal capsule (14). Spontaneous rupture of primary RCC seldom occurs only in one case (0.3% of 309 cases) (14). Another study reported 2 cases of ruptured RCC in pregnant patients who were treated for end-stage disease (6). Perioperative diagnoses are very difficult (15).

## Conclusions

All cases of hypertensive disorders in pregnancy should be investigated for secondary causes of hypertension. Abdominal

ultrasonography must be done for all cases of hypertensive disorders during pregnancy in the 2nd trimester. Even though, there are more benign causes for hematuria and hypertension during pregnancy such persistent symptoms should be evaluated for rare causes also. With the increasing usage of ultrasonography in obstetrics, such conditions should not be missed. Because renal cell carcinoma in pregnancy is potentially curable with prompt diagnosis and management. Awareness of rare events should always be kept in mind.

*Acknowledgment: Thanks to prof. Tareq & prof. Soufi for their smooth general anesthesia.*

*Availability of data and materials: The data is available.*

*Authors' contributions: Zaki Eldahshoury.M. The operator of the case revised the manuscript Hassaan A. Gad. MD writing the manuscript. Salah Ahmed. MD Writing the manuscript*

*Conflict of interest: None*

*Funding: None*

## References

- Smith LH, Danielsen B, Allen ME, Cress R. Cancer associated with obstetric delivery: Results of the linkage with the California cancer registry. *Am J Obstet. Gynecol.* 2003;189(4):1128-35. Doi: 10.1067/s0002-9378(03)00537-4. PMID: 14586366.
- Stoicescu M. Kidney Tumor in Pregnancy. *J Nephrol Ther.* 2013;3:138. Doi: 10.4172/2161-0959.1000138.
- Cancer Facts and Figures 2015. American Cancer Society. Available at <http://www.cancer.org/acs/groups/content/@editorial/documents/document/acspc-044552.pdf>. Accessed: September 29, 2015.
- Chow W-H, Dong LM, Devesa SS. Epidemiology and risk factors for kidney cancer. *Nat Rev Urol.* 2010;7(5):245-57. Doi: 10.1038/nrurol.2010.46. PMID: 20448658, PMCID: PMC3012455.
- Loughlin KR. The management of urological malignancies during pregnancy. *Br J Urol.* 1995;76(5):639-44. Doi: 10.1111/j.1464-410x.1995.tb07794.x. PMID: 8535688.
- Walker JL, Knight EL. Renal cell carcinoma in pregnancy. *Cancer* 1986;58(10):2343-7. Doi: 10.1002/1097-0142(19861115)58:10<2343::aid-cnrcr2820581031>3.0.co;2-#. PMID: 3756780.
- Smith DP, Goldman SM, Beggs DS, Lanigan PJ. Renal cell carcinoma in pregnancy: Report of three cases and review of literature *Obstet Gynecol.* 1994;83(5 Pt 2):818-20. PMID: 8159360.
- Boussios S, Pavlidis N. Renal cell carcinoma in pregnancy: a rare coexistence. *Clin Transl Oncol.* 2014;16(2):122-7. Doi: 10.1007/s12094-013-1105-2. PMID: 24002946.
- Oduagbon OE, Orumuah AJ, Enoghama UE. Renal cell carcinoma in pregnancy. *Afr J Med Health Sci.* 2013;12:49-51. Doi:10.4103/2384-5589.129930.
- Casalino DD, Remer EM, Bishoff JT, Coursey CA, Dighe M, Harvin HJ, et al. ACR appropriateness criteria post-treatment follow-up of renal cell carcinoma. *J Am Coll Radiol.* 2014;11(5):443-9. Doi: 10.1016/j.jacr.2014.01.023. PMID: 24793039.
- Bettez M, Carmel M, Temmar R, Côté AM, Sauvén, Asselah J. Fatal fast-growing renal cell carcinoma during pregnancy. *J Obstet Gynaecol Can.* 2011;33(3):258-61. Doi: 10.1016/s1701-2163(16)34827-7. PMID: 21453566.
- Tiang KW, Ng KL, Vega-Vega A, Wood S. Rapidly enlarging renal tumor during pregnancy: diagnostic and management dilemma. *J Kidney Cancer VHL.* 2014; 1(1):12-16. Doi: 10.15586/jkcvhl.2014.6.eCollection 2014. PMID: 28326245, PMCID: PMC5345512.
- Wilcox AJ, Weinberg CR, O'Connor JF, Baird DD, Schlatterer JP, Canfield RE, et al. Incidence of early loss of pregnancy. *N Engl J Med.* 1988;319(4):189-94. Doi: 10.1056/NEJM198807283190401. PMID: 3393170.
- Skinner DG, Colvin RB, Vermillion CD, Pfister RC, Leadbetter WF. Diagnosis and management of renal cell carcinoma. A clinical and pathologic study of 309 cases. *Cancer.* 1971;28(5):1165-77. Doi: 10.1002/1097-0142(1971)28:5<1165::aid-cnrcr2820280513>3.0.co;2-g. PMID: 5125665.
- Kobayashi A, Yamaguchi T, Ishihara T, Tadenuma H, Nakamura K, Ohshima T, et al. Spontaneous rupture of pancreatic metastasis from renal cell carcinoma. *Jpn J Clin Oncol.* 2004;34(11):696-9. Doi: 10.1093/jjco/hyh127. PMID: 15613561.