

# Unilateral Adrenal Infarction in Pregnancy: A Case Report

Awatef HAJJAJI<sup>1</sup>, Yosra JEMAA<sup>1</sup>, Amina MNEJA<sup>1</sup>, Ines ZOUARI<sup>1</sup>, Imen GHADDAB<sup>1</sup>, Fethi JEBALI<sup>2</sup>, Lotfi GRATTI<sup>2</sup>, Raja FALEH<sup>1</sup>

Monastir, Tunisia

## ABSTRACT

Adrenal infarction is usually associated with bilateral adrenal hemorrhage in the setting of antiphospholipid syndrome or hemodynamic variation. Few cases of unilateral non-hemorrhagic adrenal infarction have been described in the literature. Here, we report a case occurring during pregnancy. A 27-year-old woman was infected by coronavirus four months ago and presented at 35 weeks of gestation with sudden-onset right abdominal pain without contractions. Unilateral adrenal infarction was diagnosed following computed tomography. It showed an enlarged right adrenal, without hyperenhancement. The patient's adrenal hormonal function was normal. Accurate diagnosis of non-hemorrhagic adrenal infarction remains difficult as its clinical presentation is not specific. It can only be performed with adrenal imaging. Magnetic resonance imaging shows diffuse enlargement of one or both adrenals and edema on T2-weighted images. Anticoagulation therapy may be discussed. Patients should be evaluated between 3 and 6 months after the event to assess adrenal size and function. In summary, non-hemorrhagic adrenal infarction during pregnancy is probably underdiagnosed and obstetricians should be aware of this diagnostic difficulty.

**Keywords:** Adrenal infarction, Adrenal thrombosis, Endocrinology, Non-hemorrhagic adrenal infarction, Pregnancy

*Gynecol Obstet Reprod Med* 2022;28(2):186-189

## Introduction

The adrenal glands are an atypical site for thrombotic events and in the event of infarction, a search for a cause for thrombophilia is warranted. adrenal infarction is a rare clinical entity that has been described mainly as bilateral adrenal hemorrhage in patients with antiphospholipid syndrome (1). Only a few cases of unilateral non-hemorrhagic adrenal infarction

(NHAI) have been reported, most of them occurring during pregnancy (2-7).

Pregnancy is a known hypercoagulability state and thrombosis during pregnancy can unveil thrombophilia. We report here a case of spontaneous unilateral NHAI during pregnancy and review the literature to describe this clinical entity. Our objective in presenting this particular case is to highlight the importance of suspicion of adrenal infarction in a pregnant woman with severe abdominal pain. Informed consent has been obtained from the patient.

## Case Report

**Patient Information:** A 27-year-old pregnant woman (gravida 1, para 1), presented at 35 weeks of gestation to the emergency department with acute onset of right-sided abdominal pain of 5-days duration. The pain was localized and sharp in nature and associated with nausea and vomiting. There was no history of fever, chills, constipation, or urinary symptoms.

Her medical history was unremarkable, she was a non-smoker and had no history of alcohol intake. She had not used oral contraceptives and had no history of miscarriages but she was infected by coronavirus four months ago, she has received medical treatment for Coronavirus infection based on zinc, magnesium, vitamin C, and paracetamol but she has not received an anticoagulant. She was currently taking oral iron and calcium, supplements for her pregnancy.

<sup>1</sup> Department of Obstetrics and Gynecology Maternity and Neonatal Center of Monastir, Tunisia

<sup>2</sup> Department of anesthesia and reanimation, Maternity and Neonatal Center of Monastir, Tunisia

Address of Correspondence: Jemaa Yosra  
Faculty of Medicine Monastir, Department  
of Obstetrics and Gynecology Maternity  
and Neonatal Center of Monastir,  
Victoire Street Teboulba Monastir Tunisia  
jemaayosra31@gmail.com

Submitted for Publication: 12.10.2021 Revised for Publication: 18.10.2021

Accepted for Publication: 12.06.2022 Online Published: 21.06.2022

ORCID IDs of the authors:

HA: 0000-0001-6800-0806, JY: 0000-0002-8229-4166

MA: 0000-0002-2242-4424, ZI: 0000-0003-2792-0723

GI: 0000-0002-7341-199X, JF: 0000-0002-6898-2317

GL: 0000-0002-6898-585X, FR: 0000-0001-7998-9234

Quick Response Code:	Access this article online
	Website: <a href="http://www.gorm.com.tr">www.gorm.com.tr</a>
	e-mail: <a href="mailto:info@gorm.com.tr">info@gorm.com.tr</a>
	DOI:10.21613/GORM.2022.1264

**How to cite this article:** Hajjaji A, Jemaa Y, Mneja A, Zouari I, Ghaddab I, Jebali F, Gratti L, Faleh R. Unilateral Adrenal Infarction in Pregnancy: A Case Report. *Gynecol Obstet Reprod Med* 2022;28(2):186-189.

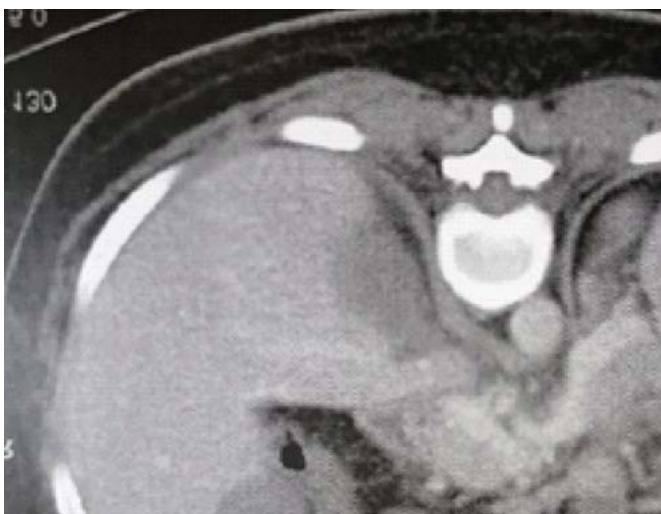


Copyright© 2022. Hajjaji et al. This article is distributed under a Creative Commons Attribution 4.0 International License.

**Clinical results:** On examination, she was in severe pain, but fully conscious and alert. Her vital signs showed a blood pressure of 122/70 mm Hg, pulse rate of 100 per minute and regular, respiratory rate of 18 per minute, a temperature of 37°C, and oxygen saturation (SpO<sub>2</sub>) of 98% on room air. Abdominal examination revealed moderate tenderness over the right upper quadrant with no rebound tenderness. There was no fundal tenderness on uterine palpation, and bowel sounds were present. Chest and cardiovascular examinations were unremarkable.

**Diagnostic procedure:** Laboratory investigations on admission were essentially unremarkable, as follows (normal ranges [NR] are shown in brackets), white blood cell count 11,410 cells/micrL (NR: 4,000-15,000/micrL), neutrophils 76.20% (NR: 40-80%), lymphocytes 17.02% (NR: 20-40%) hemoglobin level 127.2 g/L (118-148 g/L), hematocrit 0.38 L/L (0.36-0.44 L/L), mean corpuscular volume 95.93, Femtoliter (82-98 FL) and platelets 183×10<sup>9</sup>/L (150-450×10<sup>9</sup>/L). Her coagulation profile, renal function test, liver function test, electrolytes, serum amylase, and lipase were all within normal ranges. Random blood sugar was 4.5 mmol/L and routine urine microscopy did not show microscopic hematuria, proteinuria, or evidence of infection. Serum cortisol (8:00 am) was 340 nmol/L triglyceride normal. In view of the acute abdomen, ultrasonography of the abdomen was performed and revealed no evidence of acute cholecystitis or appendicitis. No free fluid was detected in the retro-peritoneum, a Doppler study for adrenal gland veins has not been practiced.

A CT Computed Tomography full abdomen scan with contrast revealed a swollen hypodense non-enhanced right adrenal gland and absence of thrombus suggestive of right adrenal infarction (Figure 1).



**Figure 1:** Swollen hypodense non-enhanced right adrenal gland suggestive of right adrenal infarction

In light of this radiological finding, which was consistent with the site of pain and acute clinical presentation, a diagnosis of right adrenal infarction was made.

**Therapeutic intervention and follow-up:** Anticoagulation with subcutaneous low-molecular-weight heparin (LMWH) 60 mg twice daily was commenced to prevent the propagation of adrenal infarction and a similar occurrence in the contralateral gland. A thrombophilia screen was sought and antinuclear antibodies (ANA), lupus anticoagulant, anti-cardiolipin antibody, and anti-glycoprotein were noted to be negative.

## Discussion

The antiphospholipid antibody syndrome has been identified as the most common risk factor for adrenal infarction (8,9). Adrenal glands are predisposed to microvascular thrombosis and infarction during procoagulable states such as coronavirus infection or during hemodynamics variation (9). Adrenal infarction without a context of hemorrhage is a rare event. Only a small number of cases of NHAI have been reported and, to our knowledge, only nine cases of unilateral NHAI during pregnancy have been published in the literature (Table I).

Based on the results from a retrospective MRI study, Glomski et al. estimated the frequency of unilateral NHAI at 1.3% among patients having an MRI for abdominal acute pain during pregnancy (7). All the cases described in the literature have a similar presentation (2,3,5-7,10,11) abdominal pain resisting usual pain medication, with other clinical signs that are mild and not specific such as tachycardia and elevated white blood cell count.

It is interesting to highlight that from the nine cases in the literature, as well as the case we report, eight involved the right adrenal gland. The main involvement of the right adrenal could be explained by its anatomical location with respect to that of the vena cava, taking into account that the return of venous blood can be impaired by the gravid uterus leading to adrenal blood stasis (12,13). The pathogenesis of adrenal infarction has been best described by Fox in his seminal paper in the Journal of Pathology (9).

He reports that most cases of adrenal infarctions are venous in nature due to thrombi in the intra-adrenal veins, venous sinuses, cortical sinuses, capsular veins, and the main extra-adrenal veins. Non-hemorrhagic adrenal infarction is a rare but important diagnostic consideration in a pregnant patient who presents with acute onset severe flank pain. In the literature, adrenal vein thrombosis has been described as a cause of adrenal infarction in pathology specimens (9).

The typical presentation of unilateral adrenal infarction is of acute onset of flank pain, nausea, and vomiting (5). Physical examination demonstrates nonspecific severe flank or abdominal tenderness, unrecognized adrenal insufficiency may lead to intrauterine growth retardation and even maternal or intrauterine death (14). No standard anticoagulation protocol has been described for adrenal infarction, but the consen-

**Table I.** Case reports of unilateral NHAJ during pregnancy published in the literature.

Authors	Clinical presentation	CT-scan or MRI results	Treatment	Follow-up	Corona infection
Aljenaee et al., 2017	Gestational Age:24 Abdominal pain	Low density and enlarged adrenal	Heparin injection	Remission	-
Sormunen-Harju et al., 2015	Gestational Age:38 Preeclampsia and abdominal pain	Low density and enlarged adrenal + venous thrombosis	Heparin injection	Remission and labor induction for preeclampsia	-
Green et al., 2013	Gestational Age:28 abdominal pain	Low density and enlarged adrenal	Heparin injection	Chorioamnionitis	-
Guenette et al., 2015	Gestational Age:27 abdominal pain	Low density and enlarged adrenal	Fondaparinux	Remission	-
Guenette et al., 2015	Gestational Age:35 Left abdominal pain	Low density and enlarged adrenal	Heparin injection	C-section for pain management	-
Riechman et al., 2015	Gestational Age:28 abdominal pain	MRI: enlarged and edematous adrenal	Heparin injection	Remission	-
Schmitt et al., 2009	Gestational Age:36 abdominal pain	Adrenal vein thrombosis	Heparin injection	C-section for pain management	-
Glomski et al., 2018	Gestational Age:33 abdominal pain	MRI: enlarged and elevated T2 signal adrenal	No treatment	Remission	-
Glomski et al., 2018	Gestational Age:16 Persisting pain after appendectomy	MRI: enlarged and elevated T2 signal adrenal	No treatment	Remission	-

sus among physicians for venous thromboembolism proposes 60 mg enoxaparin twice a day for the duration of the patient's pregnancy and 6 weeks postpartum for a minimum of 3 months, whereas the hematology team workup for prothrombotic conditions continues (15).

MRI without contrast is the imaging modality of choice. Limited CT of the abdomen with contrast may be used in cases where the diagnosis is unclear. The affected gland would likely have been hypoenhancing with respect to the normal contralateral adrenal gland.

## Conclusion

Adrenal infarction is an important diagnostic consideration in pregnant patient who presents with abdominal or flank pain. Failure to diagnose adrenal infarct predisposes the patient to adrenal insufficiency should infarction of the contralateral adrenal gland occur. This outcome of adrenal crisis would be catastrophic for both patient and fetus with severe morbidity and potentially mortality. Treatment with anticoagulation therapy should be discussed. Importantly, precautions need to be taken during the next pregnancy with a thrombophilia workup and preventive anticoagulation treatment as the risk of a contralateral event is unknown. The prevalence of NHAJ is

probably underestimated and obstetricians and midwives should be aware of such a diagnosis when being confronted with severe resistant abdominal pains.

*Acknowledgment:* We are thankful for the tireless efforts of the research team members.

*Consent:* Written informed consent for publication of their clinical details was obtained from the patient.

*Availability of data and materials:* The data supporting this study is available through the corresponding author upon reasonable request.

*Competing interests:* The authors declare that they have no competing interests.

*Funding:* We received no financial support for the research, authorship, and/or publication of this article.

*Authors' contributions:* Hajjaji Awatef and Jemaa Yosra raised the presented idea. Mneja Amina designed the study. Zouari Ines conducted the analyses. Ghaddab Imen and Jebali Fethi developed the first draft of the manuscript. All authors contributed to the writing of the paper, and have read and approved the final manuscript. Gratti Lotfi conducted the population study, analyzed and interpreted the data, and drafted the manuscript. WH participated in data analysis, interpretation, and draft revision. Faleh Raja participated in data col-

lection and result interpretation. Jemaa Yosra assisted with data collection and analysis. Mneja Amina designed the study and critically revised the manuscript. All authors read and approved the final manuscript.

## References

- Vella A, Nippoldt TB, Morris JC 3rd. Adrenal hemorrhage: a 25-year experience at the Mayo Clinic. *Mayo Clin Proc.* 2001;76(2):161-8. Doi: 10.1016/S0025-6196(11)63123-6.
- Sormunen-Harju H, Sarvas K, Matikainen N, Sarvilinna N, Laitinen EK. Adrenal infarction in a healthy pregnant woman. *Obstet Med.* 2016;9(2):90-2. Doi: 10.1177/1753495X15627959.
- Guenette JP, Tatli S. Nonhemorrhagic adrenal infarction with magnetic resonance imaging features during pregnancy. *Obstet Gynecol.* 2015;126(4):775-8. Doi: 10.1097/AOG.0000000000000884.
- Riddell AM, Khalili K. Sequential adrenal infarction without MRI-detectable hemorrhage in primary antiphospholipid-antibody syndrome. *AJR Am J Roentgenol.* 2004;183(1):220-2. Doi: 10.2214/ajr.183.1.1830220.
- Green PA, Ngai IM, Lee TT, Garry DJ. Unilateral adrenal infarction in pregnancy. *BMJ Case Rep.* 2013;2013:bcr2013009997. Doi: 10.1136/bcr-2013-009997.
- Aljenae KY, Ali SA, Cheah SK, Alroomi MJ. Unilateral adrenal infarction in pregnancy secondary to elevated factor VIII. *Saudi Med J.* 2017;38(6):654-6. Doi: 10.15537/smj.2017.6.18520.
- Glomski SA, Guenette JP, Landman W, Tatli S. Acute nonhemorrhagic adrenal infarction in pregnancy: 10-year MRI incidence and patient outcomes at a single institution. *AJR Am J Roentgenol.* 2018;210(4):785-91. Doi: 10.2214/AJR.17.18739.
- Espinosa G, Santos E, Cervera R, Piette JC, de la Red G, Gil V, et al. Adrenal involvement in the antiphospholipid syndrome: clinical and immunologic characteristics of 86 patients. *Medicine (Baltimore).* 2003;82(2):106-18. Doi: 10.1097/00005792-200303000-00005.
- Fox B. Venous infarction of the adrenal glands. *J Pathol.* 1976;119:65-89. Doi: 10.1002/path.1711190202.
- Schmitt C, Debord MP, Grange C, Ben Cheikh A, Krauth JP, Dupuis O, et al. Thrombose veineuse surrénalienne en cours de grossesse [Adrenal vein thrombosis during pregnancy]. *J Gynecol Obstet Biol Reprod (Paris).* 2010;39(1):68-71. French. Doi: 10.1016/j.jgyn.2009.09.012.
- Reichman O, Keinan A, Weiss Y, Applbaum Y, Samueloff A. Non-hemorrhagic adrenal infarct in pregnancy - a rare clinical condition diagnosed by non-contrast magnetic resonance image. *Eur J Obstet Gynecol Reprod Biol.* 2016;198:173-4. Doi: 10.1016/j.ejogrb.2015.12.021.
- Ryo E, Okai T, Kozuma S, Kobayashi K, Kikuchi A, Taketani Y. Influence of compression of the inferior vena cava in the late second trimester on uterine and umbilical artery blood flow. *Int J Gynaecol Obstet.* 1996;55(3):213-8. Doi: 10.1016/s0020-7292(96)02760-9.
- Hoen N, Ziane G, Grange C, Raudrant D, Dupuis O. Ischémie aiguë unilatérale de la glande surrénale en cours du 3e trimestre de grossesse: à propos de deux cas [Unilateral adrenal ischemia during third trimester of pregnancy: about two cases]. *Gynecol Obstet Fertil.* 2011;39(5):e73-6. French. Doi: 10.1016/j.gyobfe.2011.03.005.
- Yuen KC, Chong LE, Koch CA. Adrenal insufficiency in pregnancy: challenging issues in diagnosis and management. *Endocrine.* 2013;44(2):283-92. Doi: 10.1007/s12020-013-9893-2.